

Contents

<i>Live surgeries</i>	2
<i>Latissimus dorsi / Teres Major</i>	7
<i>L'Episcopo-Sever and RSA</i>	30
<i>Inferior trapezium</i>	38
<i>Erb Palsy</i>	43

Live surgeries

Arthroscopic assisted Latissimus Dorsi Transfer in re-tear of rotator cuff repair: Results

Jean Kany, Jean Grimberg, Philippe Valenti,

*Clinique de l'Union, Toulouse, France, ** Clinique des Lilas, Paris, France, ***Clinique Jouvenet, Paris, France

Introduction-Background

In 1988, Christian Gerber (1) was the first to describe the LD transfer for the treatment of massive and irreparable rotator cuff tear (RCT). The double incision transfer is fixed anteriorly to the subscapularis tendon and laterally to the greater tuberosity by transosseous suture. Currently for massive RCT, Christian Gerber has adapted a modified « Hoffer's paediatric procedure » (2, 3) with a double incision, axillary and superior trans-deltaïd. The « Hoffer's procedure » was introduced in 1975 for the treatment of Erb's palsy, with a single large posterior incision. In 1992 and later in 2006, Christian Gerber (4) showed clearly that the results are worse in case of subscapularis tear. This technique was later used by Miniaci (5), Warner (6) and Irlenbusch (7,8). They confirmed the importance of patient selection, with bad results in case of subscapularis tear, anterior deltoid deficit, or salvage procedure (in case of previous surgery). Valenti (9) showed worse results in case of cuff re-tear.

We presented our own experience of the « Gerber's technique » in 2007 at the orthopedic French society (10). Like many other authors, we were a little disappointed with our irreproducible results, especially in case of a bad deltoid or a salvage procedure for revision surgery. Nevertheless, patients with failed previous surgery (RC repaired with biceps tenotomy or tenodesis) are numerous, without any alternative treatment.

Yet we hypothesized (11) that the problem started not only with patient selection, bad deltoid or combined subscapularis tear, but also stemmed from the 5 non-respected specific rules of tendon transfer with the "Gerber" technique:

- 1/ The good control of the tendon zone fixation
- 2/ The good control of the physiological muscle belly tension
- 3/ A very strong bone fixation
- 4/ A mini invasive surgery for a longer tendon course
- 5/ An agonist transfer

In this paper we present a personal study to evaluate a new mini invasive and arthroscopic technique respecting 4 out of 5 rules of a tendon transfer with a 12 month minimum follow-up in case of cuff re-tear after previous RCR and biceps tenotomy/tenodesis surgery.

Materials and methods

Criteria

Inclusion criteria were a re-teared massive and irreparable postero-superior RC, with a stage 3 or superior muscle belly fatty infiltration. LHB tenotomy or tenodesis were previously performed. Exclusion criteria, according to Gerber's recommendations, were irreparable subscapularis deficiency, excentric arthritis, deltoid palsy and a pseudo paralytic shoulder.

Operative technique

Since 2007, we have developed a new LD transfer technique:

1. Taking advantage of the lax axillary fold for a mini open 5 to 10 cm axillary incision, we are able to control the pedicle, the apex scapula release of variable LD insertion and the LD humeral shaft insertion.
2. As LD tendon is flat and thin, we tubularize it in order to make a very strong transosseous fixation through a bone tunnel, as Boileau (12) proposed in 2002 for the LHB tenodesis with an Interference Screw (IFS). This « IFS technique » was adapted in our LD transfer humeral head fixation (13). Nevertheless, because of the very frequent poor quality of the metaphyseal bone, we modified our bone device fixation, first using an IFS and currently an endobutton into the bicipital groove, looking for a stronger distal and cortical fixation, with a 100% bone-tendon contact (11).

Post-operative rehabilitation

A 4-week 30° abduction sling is proposed. Passive ROM is started at D1 without any limitation, except in IR. Active exercises are started later.

Clinical assessment

Results

47 patients were included in the study. Mean age at time of surgery was 58 (31-73). Every patient had already been operated on (1 to 6 times) for a cuff repair. Mean preoperative Constant score was 32,28 (25-39), preoperative SSV score was 20,6 % (16-24). No patients were ignored. At review, Constant score was to 58,76 (50/67), mean postoperative SSV score was 67,62% (56/76), 31 (74%) patients were satisfied or very satisfied; 4 (9,5%) were disappointed, 7 (16,5%) were not satisfied.

Discussion

Hoffer's procedure (2,3) was described in pediatric surgery, for a neurological pathology, with an IR contracture. On the opposite, Gerber's procedure (1) is proposed in adult surgery for tendon deficiency and with normal passive ROM. Surprisingly the same technique is used for two different indications: results should be different. In addition Gerber's procedure does not respects five tendon transfer rules perfectly.

The first point is to get a perfect fixation zone control directly onto the bone as close as possible to the joint. Indeed, according to Walch (13), the clinical presentation of patients with a massive RCT is variable, especially in case of positive or negative Drop sign or Horn blower sign. In case of a negative Drop Sign but painful shoulder ("PLAE "described by Boileau), meaning an active posterior cuff, according to Gerber (1) and using a special guide, we propose an « over the top » transfer fixation zone, beyond the centre of rotation of the joint in order to get a passive and active depressor transfer action in combination with the forward flexion. In case of a positive Drop Sign or Horn blower sign, meaning an inactive posterior cuff (ILER, described by Boileau (14)), according to Habermeyer (15) or to Herzberg (16), and using a special guide, we propose to fix the tendon more posteriorly, behind the centre of rotation of the HH, looking for an active external rotation transfer. This arthroscopic technique allows a very accurate area of LD fixation.

The second point is to control the muscle belly tension. Indeed, insufficient tension leads to a non-effective transfer.

Conversely, too much tension leads to non-physiological conditions, and probably histopathological lesions. In order to obtain the best appropriate tension, we put two landmarks on the muscle belly before the tenotomy, in maximum abduction and internal rotation. After tenotomy, the tension has to match the original one in maximum abduction and external rotation.

The third point is the quality of the bone. Since this metaphyseal bone is frequently fragile, a very strong fixation device is necessary. A cadaveric biomechanical study was published by Chang and Grimberg (17). Compared to the standard anchor fixation, the IFS technique with a tabularized tendon presents higher biomechanical performances.

The fourth point is to prevent a very invasive and large dissection in order to get a better healing around the tendon and consequently a longer course. Furthermore it preserves the deltoid muscle belly against an iterative approach.

Nevertheless, LD is not an agonist of forward flexion and external rotation. Last but not least, this 5th rule is not respected by our transfer. Perhaps this is the main reason for our incomplete or imperfect results.

Conclusion

RC re-tear still is a surgical challenge. After a 12-month follow-up, @ assisted LDT results are better than those reported by Gerber. This new technique should be a considered option for failed and painful RCR. This technique respects 4 of the 5 rules of a tendon transfer with, first, a good control of the tendon zone fixation depending on the drop sign. Secondly, a good control of the physiological muscle belly tension. Thirdly it gives a very

strong bone fixation with a 100% bone-tendon contact for better healing, and finally, a mini invasive surgery for a longer course. Nevertheless, LD is not an agonist of forward flexion and external rotation. Consequently, post-operative care and physiotherapy have a major importance.

References

- (1) Gerber C, Vinh TS, Hertel R et al. Latissimus dorsi transfer for the treatment of massive tears of the rotator cuff. A preliminary report. Clin Orthop. 1988; 232:51-61.
- (2) Hoffer MM, Wickenden R, Roper B. Brachial plexus birth palsies. Results of tendon transfers to the rotator cuff. J Bone Joint Surg Am. 1978 Jul; 60(5):691-695.
- (3) Phipps GJ, Hoffer MM.: Latissimus dorsi and teres major transfer to rotator cuff for Erb's palsy. J Shoulder Elbow Surg. 1995; 4:124-9.
- (4) Gerber C. Latissimus dorsi transfer for the treatment of irreparable tears of the rotator cuff. Clin Orthop. 1992; 275:152-60.
- (5) Miniaci A, Mcleod M. Transfer of the latissimus dorsi muscle after failed repair of a massive tear of the rotator cuff. A two to five-year review. J Bone Joint Surg Am. 1999; 81:1120-7
- (6) Warner JJ. Management of massive irreparable rotator cuff tears: the role of tendon transfer. J Shoulder Elbow Surg. 2001; 10:514-21
- (7) Irlenbusch U, Bracht M, Gansen HK, et al. Latissimus dorsi transfer for irreparable rotator cuff tears: A longitudinal study. J Shoulder Elbow Surg. 2008; 17:527-34.
- (8) Irlenbusch U, Bendsdorf M, Gansen HK, et al. Latissimus dorsi transfer in case of irreparable rotator cuff tear: , a comparative analysis of primary and failed rotator cuff surgery, in dependence of deficiency grade and additional lesions. Z Orthop Ihre Grenzgeb. 2003; 141:650-6
- (9) Valenti Ph, Kalouche I, Diaz LC, Kaouar A, Kilinc A. Results of latissimus dorsi tendon transfer in primary or salvage reconstruction of irreparable rotator cuff tears. Orthop Traumatol Surg Res. 2010 Apr; 96 (2):133-138. doi:10.1016/j.rcot.2010.02.018
- (10) Kany J, Lasseur E, Tramond P. Traitement des ruptures irréparables de la coiffe des rotateurs par lambeau de grand dorsal : intérêt d'une nouvelle technique de fixation transosseuse. Rev Chir Orthop Reparat App. 01/2007; 93(7):36-36.

- (11) Goldstein Y, Grimberg J, Kany J, Valenti P, Chechik O, Drexler M. Arthroscopic fixation with a minimally invasive axillary approach for latissimus dorsi transfer using an endobutton in massive and irreparable postero-superior cuff tears. *Int J Shoulder Surg.* 2013; 7 (2):79. doi:10.4103/0973-6042.114223
- (12) P. Boileau, S. Krishnan, J.S. Coste, G, et al. Arthroscopic biceps tenodesis: a new technic using interference screw. *Techniques in Shoulder and Elbow Surgery* 2001;2: 153-165.
- (13) Kany J, Kumar HA, Chang WK, Grimberg J, Garret J, Valenti Ph. Mini Invasive Axillary Approach and Arthroscopic Humeral Head Interference Screw Fixation for Latissimus Dorsi Transfer in Massive and Irreparable Posterosuperior Rotator Cuff Tears. *Tech Should Surg* 2010; 11: 8-14.
- (13) Walch G, Boulahia A, Calderone S. The “dropping” and “hornblower’s” signs in evaluation of rotator cuff tears. *J Bone Joint Surg* 1998; 80-B:624-8.
- (14) Boileau P1, Chuinard C, Roussanne Y, Neyton L, Trojani C : Modified latissimus dorsi and teres major transfer through a single delto-pectoral approach for external rotation deficit of the shoulder: as an isolated procedure or with a reverse arthroplasty. *J Shoulder Elbow Surg.* 2007 Nov-Dec; 16 (6):671-82.
- (15) Habermeyer P, Magosch P, Rudolph T, et al. Transfer of the tendon of latissimus dorsi for the treatment of massive tears of the rotator cuff: a new single-incision technique. *J Bone Joint Surg Br.* 2006; 88:208-12.
- (16) Herzberg G, Urien JP, Dimnet J: Potential excursion and relative tension of muscles in the shoulder girdle: relevance to tendon transfer. *J Shoulder Elbow Surg.* 1999; 8:430-7.
- (17) Diop A, Maurel N, Chang VK, Kany J, Duranthon LD, Grimberg J. Tendon fixation in arthroscopic latissimus dorsi transfer for irreparable posterosuperior cuff tears: an in vitro biomechanical comparison of interference screw and suture anchors. *Clin Biomech (Bristol, Avon).* 2011 Nov; 26(9): 904

Latissimus dorsi / Teres Major

Generalities about the latissimus dorsi and teres major

Kevin BARGOIN - Nantes

The latissimus dorsi (LD) is the larger, flat, dorso-lateral muscle on the trunk¹. Origin of the latissimus dorsi is from spinous processes of thoracic T7 to T12, thoracolumbar fascia, sacral vertebrae, posterior iliac crest, lower 3 or 4 ribs and inferior angle of scapula. It is partly covered by the trapezius on its median dorsal region. Distal Flat tendon that twists upon itself to insert into the intertubercular groove of the humerus, just anterior to and parallel with the tendon of pectoralis major. The average width of the latissimus dorsi tendon at its insertion site is 3.1 cm (2.4 - 4.8 cm), and the average length of the tendinous portion is 8.4 cm (6.3 - 10.1 cm)²⁻⁴. There are always fascial connections between the latissimus and teres major and between the latissimus and the long head of the triceps a band of tissue representing the remnant of the dorsoepitrochlearis brachii of apes.

The teres major (TM) originates from the inferior angle of the scapula and inserts on the medial lip of the bicipital groove of the humerus, posterior to the insertion of the latissimus dorsi. The average width of the teres major tendon at its insertion site is 4.0 cm (3.3 to 5.0 cm), and the average length is 3.9 cm (3.3 to 4.6 cm)⁵.

From the posterior axillary approach, maximal internal rotation of the humerus facilitate exposure for tenotomy by delivering the tendons latissimus dorsi and teres major tendon insertion sites into the surgical with an average of 1.9 cm gain.

Different patterns tendons insertions

The tendons of the teres major and latissimus dorsi muscles near their insertions were found to have 3 distinct patterns.

The first insertional pattern (67%) had separate and distinct tendons of the latissimus dorsi and the teres major. These tendons can be separated by gentle finger dissection.

The second insertional pattern (25%) consisted of a common tendinous insertion of the latissimus dorsi and teres major. These tendons can be separated only with sharp division of fibrous connections.

In the third insertional pattern (8%), tendons are completely conjoined and cannot be separated.

Vascularization

Blood is supplied to the latissimus dorsi muscle via the thoracodorsal artery, a branch of subscapular artery. The subscapular artery, a branch of the axillary artery, sends off a circumflex scapular branch posteriorly, then distributes a serratus branch before it enters the muscle on its undersurface as the thoracodorsal artery^{6,7}. A single venae comitantes typically accompanies the artery. The pedicle can be approached by following the undersurface of the muscle in a distal to proximal approach.

The vascular supply of the teres major muscle derived from the circumflex scapular artery, a branch of the subscapular artery. The teres major appeared to have a predominant artery, the predominant artery is a branch of the subscapular artery in 2/3 of the cases⁸.

Nerve Supply and relationship of the radial and axillary nerve to the latissimus dorsi and teres major tendons

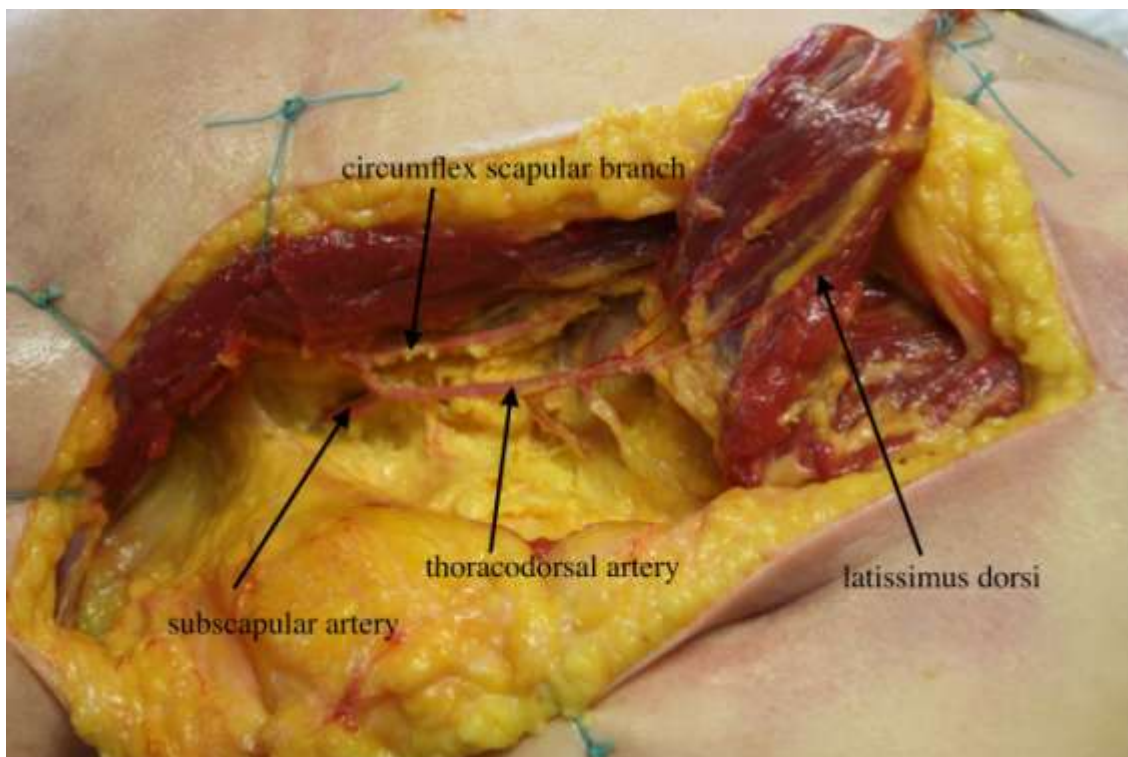
The latissimus dorsi is supplied by the sixth, seventh, and eighth cervical nerves (posterior cord of the brachial plexus) through the thoracodorsal nerve

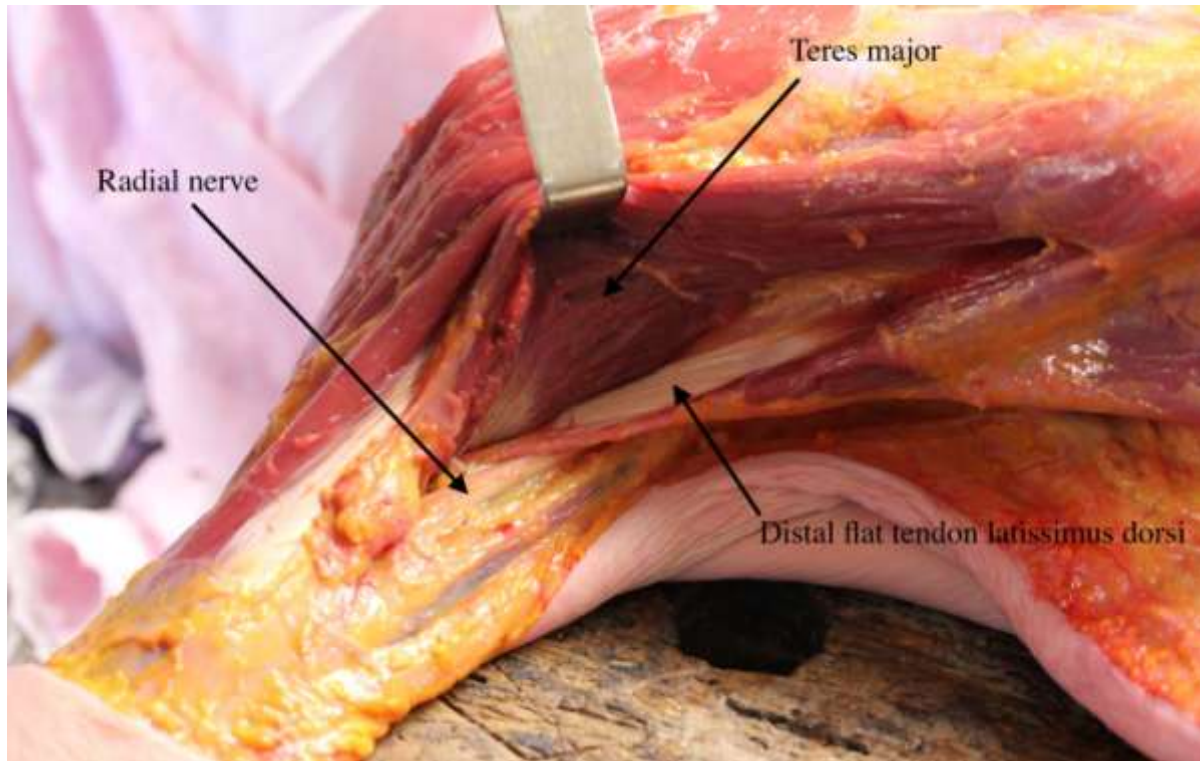
The nerve to the teres major, the lower subscapular nerve, arose from the posterior cord (C5, C6) of the brachial plexus and entered, with the artery, the antero-superior edge of the muscle at approximately 4.1 cm (2.0-6.2 cm) from the scapular origin³.

The radial nerve cross the anterior aspect of the latissimus dorsi and teres major tendons at an average of 2.9 cm (2.0 to 4.0 cm) to the superior aspect and 2.3 cm (1.6 to 3.4 cm) medial to the inferior aspect of the humeral insertions.

At the level of the latissimus dorsi insertion on the humerus, the radial nerve is encased in fatty tissue and coursed medial to the intermuscular septum between the anterior and posterior compartments of the arm.

The axillary nerve is slightly posterior and proximal to the insertion of latissimus and is covered by a fibrous sheath. The axillary nerve is an average of 1.4 cm (0.8 to 2.0 cm) proximal to the superior edge of the teres major, which extended superior to the latissimus dorsi tendon at this level.





- 1 Stoller, D. *Atlas of orthopaedics and sports medicine*. (2008).
- 2 Grimberg, J. & Kany, J. Latissimus dorsi tendon transfer for irreparable postero-superior cuff tears: current concepts, indications, and recent advances. *Curr Rev Musculoskelet Med*, doi:10.1007/s12178-013-9196-5 (2014).
- 3 Schoierer, O. *et al*. Anatomical basis of latissimus dorsi and teres major transfers in rotator cuff tear surgery with particular reference to the neurovascular pedicles. *Surg Radiol Anat* **23**, 75-80 (2001).
- 4 Goldberg, B. A., Elhassan, B., Marciniak, S. & Dunn, J. H. Surgical anatomy of latissimus dorsi muscle in transfers about the shoulder. *Am J Orthop (Belle Mead NJ)* **38**, E64-67 (2009).
- 5 Wang, A. A., Strauch, R. J., Flatow, E. L., Bigliani, L. U. & Rosenwasser, M. P. The teres major muscle: an anatomic study of its use as a tendon transfer. *J Shoulder Elbow Surg* **8**, 334-338 (1999).
- 6 Mathes, S. J. & Nahai, F. Classification of the vascular anatomy of muscles: experimental and clinical correlation. *Plast Reconstr Surg* **67**, 177-187 (1981).
- 7 Pearle, A. D., Kelly, B. T., Voos, J. E., Chehab, E. L. & Warren, R. F. Surgical technique and anatomic study of latissimus dorsi and teres major transfers. *J Bone Joint Surg Am* **88**, 1524-1531, doi:88/7/1524 [pii] 10.2106/JBJS.E.00426 (2006).
- 8 Valenti, P. *Tendon transfe for irreparable cuff tear*. (2011).

Massive RCT: Proposition for a new classification. How to restore muscular balance?

Nicolas Bonneville , Pascal Boileau
Nice, France

Background

The shoulder is naturally unbalanced; in vertical plane, there is a predominance of the deltoid muscle over the rotator cuff muscles. In horizontal plane, 4 muscles are internal rotators (subscapularis, pectoralis major, teres major and latissimus dorsi) and only 2 are external rotators (infraspinatus, teres minor).

Therefore, in case of massive rotator cuff tear (cuff wear), the key question is in which plane the shoulder is unbalanced: Vertical ? Horizontal ? or Both?

Classification

3 patterns of presentation with irreparable massive cuff tear should be taken into account:

- **ILEA: Isolated Loss of Active Elevation.** This is an imbalance in vertical plane with an upward migration of the humeral head. Clinically, patients are unable to elevate or abduct more than 90° (i.e pseudoparalysis). (**Figure 1**)
- **ILER: Isolated Loss of External Rotation.** This is an imbalance in horizontal plane between intact internal rotator muscles and the absent or atrophied infraspinatus and teres minor (external rotators). Because there is no other muscle to provide active external rotation, any attempt at shoulder elevation results in the forearm dropping and such patients cannot control the upper limb in the space with wide consequences on daily living activities. (**Figure 2**)
- **CLEER: Combined Loss of Elevation and External Rotation.** There is a vertical and an horizontal imbalance: pseudoparalyzed shoulder (AAE<90°) with inability to maintain the arm in neutral rotation when the elbow is at side. (**Figure 1**)

Algorithm for treatment: looking for a new balance !

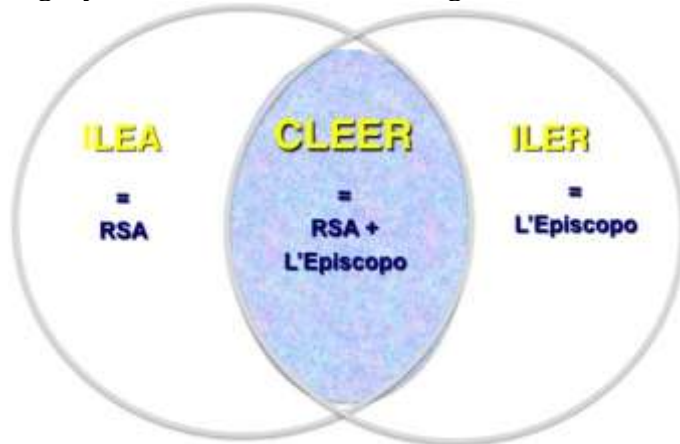


Figure 1: ILEA (Isolated Loss of Active Elevation): lose active elevation but preserved external rotation.

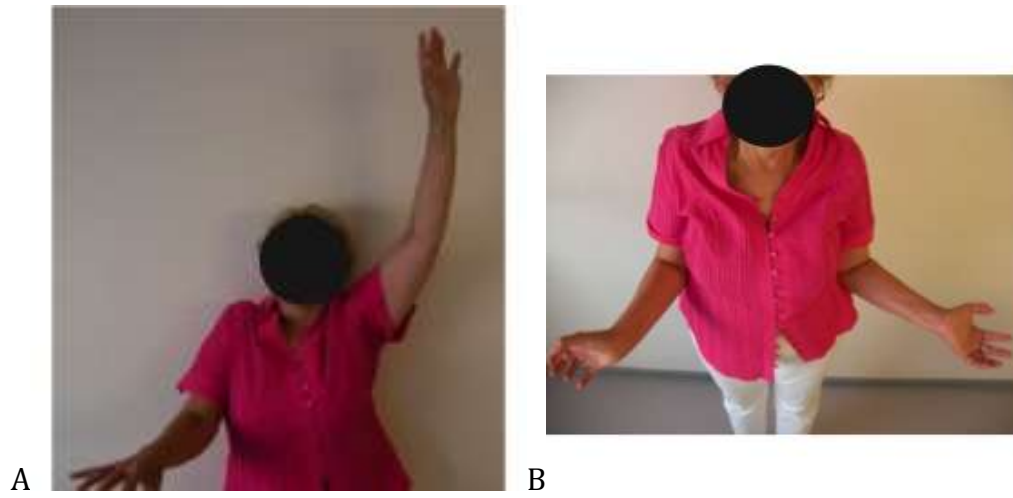

Figure 2: ILER: Isolated Loss of External Rotation

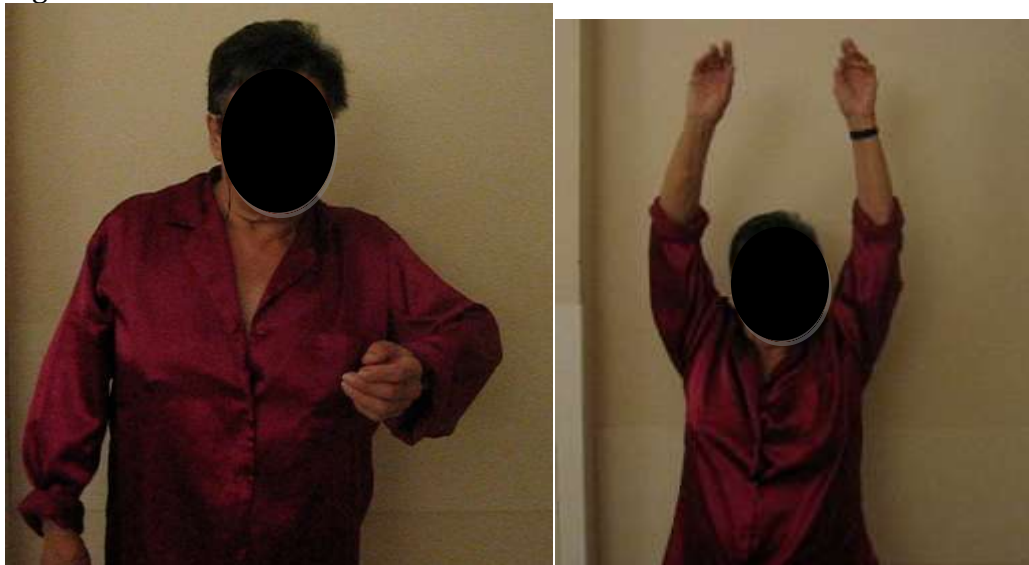
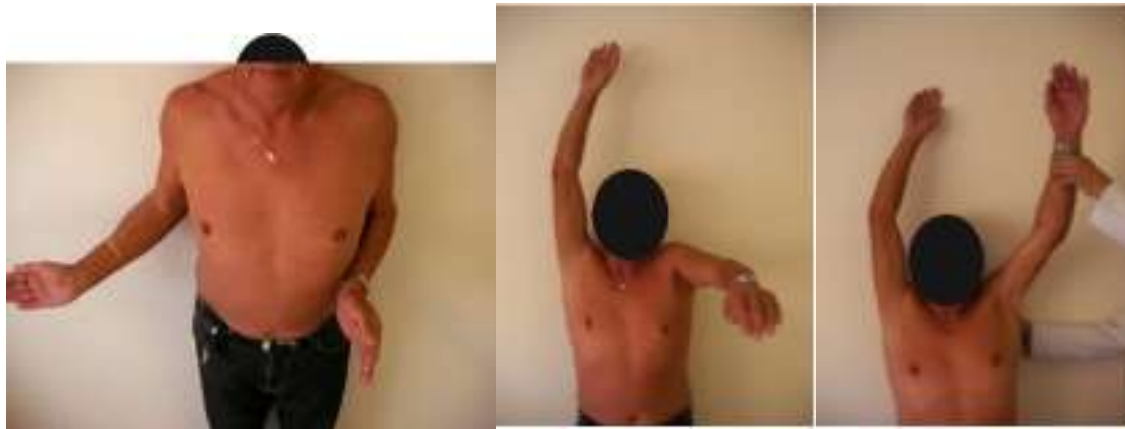
Figure 3 CLEER: Combined Loss of Elevation and External Rotation.



References

Burkhart SS et al., Fluoroscopic comparison of kinematics pattern in massive rotator cuff tears. A suspension bridge model. CORR 1992, 284;146

Boileau P et al. Modified latissimus dorsi and teres major transfer through a single deltopectoral approach for external rotation deficit of the shoulder: as an isolated procedure or with a reverse arthroplasty. J Shoulder Elbow Surg. 2007 Nov-Dec;16(6):671-82.

Boileau P, et al. Reverse shoulder arthroplasty combined with a modified latissimus dorsi and teres major tendon transfer for shoulder pseudoparalysis associated with dropping arm. Clin Orthop Relat Res. 2008 Mar;466(3):584-93.

Boileau P et al. Grammont reverse prosthesis: design, rationale, and biomechanics. J Shoulder Elbow Surg. 2005 Jan-Feb;14(1 Suppl S):147S-161S.

BIOMECHANICAL RATIONALE OF TENDON TRANSFER IN THE SHOULDER FOR POSTEROSUPERIOR CUFF TEAR

Jean GRIMBERG - Paris

I INTRODUCTION

The aim of tendon transfer in the shoulder is to balance shoulder forces in a postero-superior cuff deficient shoulder in order to allow decrease of pain and better movements of the joint. A Secondary aim would be an increase of shoulder strength but it is not always possible.

This presentation will give a specifically shoulder oriented approach of general biomechanics of tendon transfers and analyse the few specific biomechanical studies published on LD and TM transfer for posterosuperior cuff tears.

II MUSCLE TRANSFER CONDITIONS

1°) Potential excursion and relative tension: those two items should normally be similar between the transferred tendon and the original tendon.

Potential tension is related to the length of the transferred tendon and has been well studied for shoulder muscle by Herzber et al. Relative tension is an item which is related to strength of the muscle.

Table 1 : potential excursion (PE) and relative tension (RT) of muscles around the shoulder (Herzberg et al.)

MUSCLE	PE (cm)	RT (%)
Subscapularis	7,3	14,5
Pec Major (clavicular)	14,5	2,3
Pec Major (sternal)	18,8	5,4
Supraspinatus	6,7	5,2
Infraspinatus	8,6	9,7
Latissimus dorsi	33,9	5,9
Teres major	14,9	4,3
Anterior deltoïd	11,5	3,4

In the above table, one may see that the potential excursion of the LD is largely enough to allow the LD tendon to reach the superior aspect of the humeral head. The potential

excursion of TM is less important but still enough to allow TM transfer around the humeral head.

However, relative tension shows that LD and TM are less powerful than supraspinatus and even less than infraspinatus. This may partially explain why LD and/or TM tendon transfer do not allow restoration of shoulder strength.

2°) Direction of pull

The direction of pull of the transferred tendon should be similar to the direction of the original tendon.

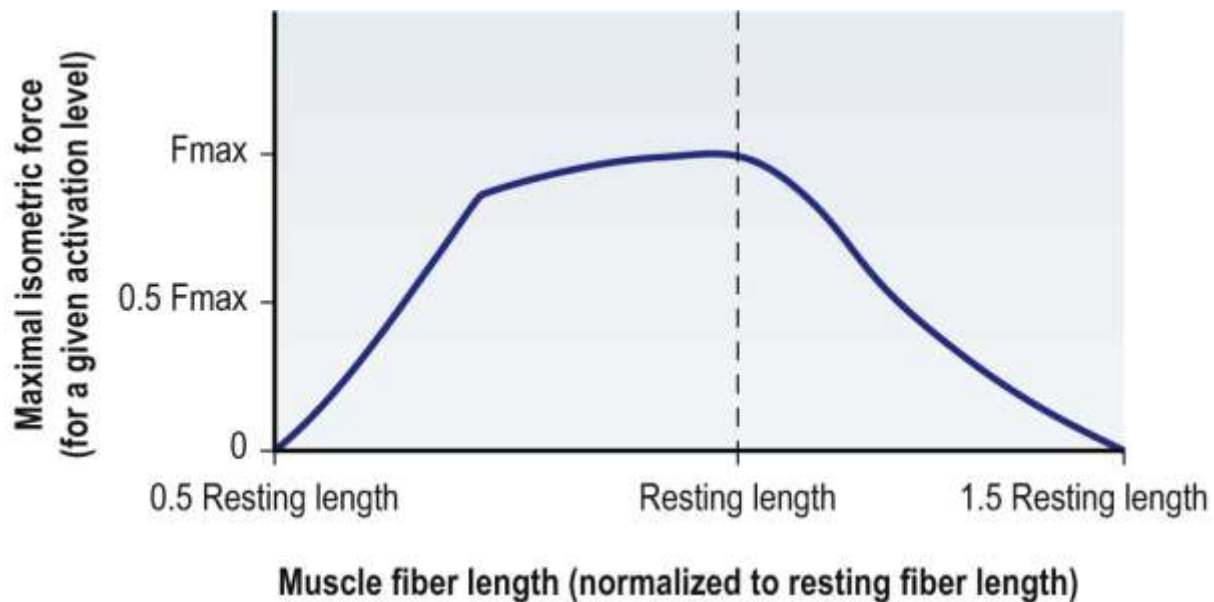
The direction of LD and TM muscle are different from the direction of supraspinatus and similar to the direction of the infraspinatus.

3°) Localisation of the neurovascular pedicle

The neurovascular pedicle of the LD tendon allows more than 8 cm of excursion before being in danger which is largely enough to allow transfer of the LD tendon to the humeral head.

4°) Pretensioning of the musculotendinous unit.

Globally, the length of the muscle where it has the best power is the length of the muscle at rest which should be reproduced as adequately as possible during transfer.



5°) As less aggressive dissection as possible.

This condition is made easier with arthroscopic assisted technique, which is possible with our LD arthroscopic assisted transfer technique but has not been performed yet with TM transfer to our knowledge

III BIOMECHANICAL STUDIES

1°) Finite element studies

Three studies have been published on the subject (Magermans et al, Ling et al.)

Global conclusions are as follows:

Latissimus dorsi and teres major

Become anteflexor and external rotator of the humerus if transferred to supraspinatus insertion

are more external rotators if transferred on the infraspinatus insertion

LD stays retroflexor and internal rotator if fixed too anteriorly (upper subscap) or too inferiorly (teres minor)

TM has more strength than the LD

Teres Major alone or Teres Major + Latissimus Dorsi give better simulation of movements than Latissimus Dorsi alone.

Naturally those studies are finite element studies which do not take into account all the parameters that may be encountered in reality.

2°) In vitro studies

Aoki et al. in 1997 showed an increase of tensile force of 53% if LD tendon was augmented with a teflon band.

Werner et al showed in 2006 that LD transfer without subscapularis had a anterior dislocation effect.

More recently in 2013, Oh et al. showed that a massive postero-superior cuff tear leads to abnormal kinematics of the shoulder with postero-superior shift and internal rotation of the humeral head. The normal kinematics of the shoulder are restored by the LD tendon transfer.

Finally, Diop et al. showed in 2011 that a tubularized tendon in a humeral head tunnel fixed with an interference screw had higher stiffness and less displacement under loading than a flat tendon fixed onto the surface of the humeral head with anchors.

IV REFERENCES

Aoki M, Fukushima S, Okamura K, Yamada Y, Yamakoshi K. Mechanical strength of latissimus dorsi tendon transfer with Teflon felt augmentation. *J Shoulder Elbow Surg* 1997 ; 6 : 137-42.

Diop A, Maurel N, Chang VK, Kany J, Duranthon LD, Grimberg J Tendon fixation in arthroscopic latissimus dorsi transfer for irreparable postero-superior cuff tears: an in vitro biomechanical comparison of interference screw and suture anchors. *Clin Biomech* 2011 ; 26 : 904-9.

Goldstein Y, Grimberg J, Valenti P, Chechik O, Drexler M, Kany J. Arthroscopic fixation with a minimally invasive axillary approach for latissimus dorsi transfer using an endobutton in massive and irreparable postero-superior cuff tears. *Int J Shoulder Surg*. 2013; 7 : 79-82.

Hansen ML, Otis JC, Johnson JS, Cordasco FA, Craig EV, Warren RF. Biomechanics of massive rotator cuff tears: implications for treatment. *J Bone Joint Surg Am* 2008; 90 : 316-25.

Hartzler, RU, Barlow, JD, An K-A, Elhassan, BT. Biomechanical effectiveness of different types of tendon transfers to the shoulder for external rotation. *J Shoulder Elbow Surg*. 2012; 21 : 1370-6.

Hertzberg G, Urien JP, Dimnet J. Potential excursion and relative tension of muscles in the shoulder girdle: relevance to tendon transfers. *J Shoulder Elbow Surg*. 1999 ; 8 : 430 -7.

Kany J, Kumar HA, Chang VK, Grimberg J, Garret J, Valenti P. Mini invasive axillary approach and arthroscopic humeral head interference screw fixation for latissimus dorsi transfer in massive and irreparable postero-superior rotator cuff tears. *Tech Shoulder Elbow Surg* 2010 ; 11 : 8-14.

Ling HY, Angeles, JG, Horodyski MB. Biomechanics of latissimus dorsi transfer for irreparable posterosuperior cuff tears. *Clin Biomech* 2009 ; 24 : 261-66.
19 : 116-22.

Magermans DJ, Chadwick EKJ, Veeger HEJ, Rozing PM, Van der Helm FCT. Effectiveness of tendon transfers for massive rotator cuff tears : a simulation study. *Clin Biomech* 2004 : 116-122

Magermans DJ, Chadwick EKJ, Veeger, HEJ, Van der Helm FCT, Rozing PM. Biomechanical analysis of tendon transfers for massive rotator cuff tears. *Clin Biomech* 2004 ; 19 : 350-7.

Oh JH, Tilan J, Chen YC, Chung KC, MacGarry MH, Lee TH. Biomechanical effect of latissimus dorsi tendon transfer for irreparable massive cuff tear. *J Shoulder Elbow Surg.* 2013 ; 22 : 150-7.

Werner CML, Zingg PO, Lie D, Jacob HAC, Gerber C. The biomechanical role of the subscapularis in latissimus dorsi transfer for the treatment of irreparable rotator cuff tears. *J Shoulder Elbow Surg* 2006 ; 15 : 736-42

Outcome of the open Latissimus Dorsi tendon transfer (Gerber's technique)

Laurent Nove Josserand
Centre Orthopédique Santy
LYON

In 1987, Gerber proposed the latissimus dorsi tendon transfer to deal with irreparable rotator cuff tear. At this time, an irreparable tear was defined as a tear which cannot be repaired onto the greater tuberosity even though the arm was in a position of abduction of 60°. In this first paper, Gerber developed the concept of this transfer learned from pediatric surgery and demonstrated its feasibility in adults according to a cadaveric study. He described the surgical technique and the preliminary results about 4 cases (mean age 66 years). The harvested latissimus dorsi tendon went under the posterior deltoid to be fixed laterally and anteriorly onto the humeral tuberosities. The latissimus dorsi muscle and tendon were brought over the top of the humeral head and were repaired anteriorly to the subscapularis, laterally to the greater tuberosity and if possible, medially to the torn retracted edges of the rotator cuff.

The Latissimus Dorsi transfer was more popular after the publication which reported the results of 16 cases in 1992.

The results of 69 cases (mean age 61 years) were published in 2006. Indications were non repairable tear of, *at least*, the supraspinatus and infraspinatus tendon. Surgery was proposed after failure of the medical treatment if the patient was symptomatic and/or presented a significative external rotation lag. The mean follow up was 53 months. The outcome was satisfactory, especially on the subjective rather than objective criterias. SSV improved significantly, pain decreased dramatically, range of motion improved (gain was 19° in forward elevation and 7° in external rotation) but strength did not changed. The Constant score improved from 46 to 60 points postoperatively. Osteoarthritis progressed slightly and subacromial space decreased by an average of 1,5 mm.

Gerber pointed out that improvement of the subjective outcomes were larger than objective. In addition, he identified and defined contraindication and prognostic factors. He confirmed that the subscapularis status was important as previously suspected. A complete tear, retracted associated to a fatty infiltration stage 3 or more, is considered as a true contraindication to the latissimus dorsi transfer. A subscapularis tear which can be repaired represents a factor of poorer outcome. This was confirmed by biomechanical study. A previous rotator cuff surgery was also identified as a factor of poorer prognosis. Most of the authors agreed with these two findings.

Gain in range of motion needs to be discussed. « Pseudoparesis shoulder » was recognized as a contraindication by most of the authors. Gerber considers chronic pain-free pseudoparesis, with less than 30° of forward elevation, or associated with antero-superior

subluxation of the humeral head underneath the coraco-acromial arch need to be managed with reverse prosthesis. Iannotti demonstrated that preoperative range of motion (both forward elevation and external rotation) and strength were the most significant predictors of outcome. Thus, comparing the gain in forward elevation in the literature, it is varying from 14° to 63° depending from the preoperative range of motion. In some study, the mean forward elevation was inferior to 90° as observed in pseudoparesis shoulder. Considering Gerber's publications, the gain decreased from 87° in 1987, to 52° in 1992, 19° in 2006 and 14° in 2013 corresponding respectively to 62°, 83°, 104° and 118° of preoperative forward elevation. The recovery of preoperative range of motion by rehabilitation appears to be of crucial interest.

Considering active external rotation, the latissimus dorsi transfer permit to recover functional motion. The gain varied from 7° (Gerber, to 37° (Warner 2001). Costocours et al (2007) demonstrated that the quality of the teres minor improved the outcome specially considering active external rotation. Tear of the teres minor is responsible of pseudoparesis of external rotation. Despite a less important recovery in these cases, severe loss of active external rotation represents a good indication of the latissimus dorsi transfer because it is an severe handicap in the daily activities.

Other factors affecting negatively the quality of the outcome are age, gender (female), deltoid impairment, general weakness or low motivation.

It is difficult to determine the effect of the latissimus dorsi tendon transfer : tenodesis effect or synergistic active effect. EMG study and clinical palpation demonstrated activity during forward elevation and external rotation in some cases. These constatations are associated with better outcome.

It is also very difficult to assess the transfer integrity. Due to the weakness and the thickness of the latissimus dorsi tendon, the humeral fixation could be uncertain. Some authors proposed tendon augmentation (Aoki 1996) or harvesting of the tendon with bone (Moursy) to improve and secure the fixation of the transferred tendon.

Recently, Gerber reported the outcome with a minimum 10 years follow-up of a population of 46 shoulders (mean age 56 years). Clinical outcomes, subjective and objective, were durable with time. There was a slight but significant increase in osteoarthritis changes but inferior of those observed in cases of medical treatment of rotator cuff massive tear. He also individualized a large critical shoulder angle as a negative factor as subscapularis insufficiency and fatty infiltration of the teres minor.

In summary, latissimus dorsi tendon transfer is a reliable treatment for irreparable cuff tear concerning the supraspinatus, infraspinatus and at least teres minor. Severe chronic pseudoparesis shoulder, antero-superior subluxation of the humeral head, complete subscapularis tear with grade 3 fatty infiltration are considered as true contraindication. Results are better if prognostic factors were taken in account.

Bibliography :

- Gerber C, Vinh TS, Hertel R, Hess CW

Latissimus dorsi transfer for the treatment of massive tears of the rotator cuff. A preliminary report.

Clin Orthop. 1988 ; 232 : 51-61

- Gerber C

Latissimus dorsi transfer for the treatment of irreparable tears of the rotator cuff.

Clin Orthop. 1992 ; 275 : 152-160

- Gerber C, Maquiera G, Espinosa N.

Latissimus dorsi transfer for the treatment of irreparable rotator cuff tears.

J Bone Joint Surg Am. 2006 ; 88 : 113-120

- Gerber C, Rahm SA, Catanzaro S, Farshad M, Moor BK.

Latissimus dorsi tendon transfer for the treatment of irreparable posterosuperior rotator cuff tears.

J Bone Joint Surg Am. 2013 ; 95 : 1920-1926

- Iannotti JP, Hennigan S, Herzog R, Kella S, Kelley M, Leggin B, Williams GR

Latissimus dorsi tendon transfer for irreparable posterosuperior rotator cuff tears. Factors affecting outcome.

J Bone Joint Surg 2006, 88-A : 342-348

ARTHROSCOPIC ASSISTED LD TRANSFER IN MASSIVE POSTEROSUPERIOR IRREPARABLE CUFF TEARS. a multicenter prospective study

Jean GRIMBERG - Paris

Purpose: To evaluate in a multicenter prospective study the clinical, MRI and radiological results of arthroscopic assisted latissimus dorsi(LD) tendon transfer for irreparable postero-superior rotator cuff tears. To assess the influence of preoperative and peroperative datas on clinical results.

Methods: Fifty five patients with irreparable tears of at least supra and infraspinatus tendons were managed with arthroscopic assisted LD tendon transfer and reviewed clinically, with standardized radiographs and MRI after an average of twenty nine months. Average age at time of surgery was sixty two years. Outcomes measures included the Constant and Murley score and the Subjective Shoulder Values. Osteoarthritis and acromiohumeral distance were measured on standardized radiographs and transferred tendon aspect on MRI.

Results: Thirty patients had already undergone one or more previous surgeries. The mean Subjective Shoulder Value increased from 26% preoperatively to 71% postoperatively. The Constant and Murley score improved from 37 preoperatively to 65.4 postoperatively. The pain score increased from 1.7 preoperatively to 12.6 postoperatively, the activity score from 6.4 to 13.8, the active anteflexion from 134° to 157°, the active abduction from 67° to 92.5°, the active external rotation from 29° to 41.5°, the abduction strength from 1.4 kg to 4.8 kg. The only statistically significant factor influencing negatively the Constant score was previous surgery. Four patients had a ruptured latissimus dorsi tendon on MRI control at one year. There was no statistical difference between preoperative and final follow-up acromiohumeral distance. There was no increase in osteoarthritic stage.

Conclusion: arthroscopic assisted LD tendon transfer improves shoulder pain and function in patients with irreparable postero superior cuff tears with similar clinical and radiological results compared to open techniques. Previously operated patients have decreased results compared to non previously operated patients.

Latissimus dorsi transfer assisted by arthroscopy for irreparable postero superior cuff tear: indications and contraindications

Philippe VALENTI - Paris

Indications:

This tendon transfer is indicated for painful patients with irreparable supra and infraspinatus tear after failure of conservative treatment or after failure of a previous surgical treatment (debridement, biceps tenotomy or tendesis, attempt of repair). Fatty infiltration (according to Goutallier classification) equal to or over three for at least one of the two torn tendons is correlated with an irreparable cuff tear. Clinically, the forward elevation is limited around 90° with an anterior impingement. The lack of active external rotation the arm at the chest and in 90° of abduction (hornblower sign) is correlated with an associated lesion of the teres minor. Latissimus dorsi transfer is still indicated but with a fixation more posteriorly at the level of the insertion of the infraspinatus.

Contraindications:

Pseudoparalytic shoulder (Active anterior elevation <60° with an antero superior escape of the humeral head).

Massive subscapularis tear (>3 Lafosse classification)

Axillary nerve lesion

Paralysis of the deltoid

Osteoarthritis of the gleno humeral joint >2 (samilson classification)

Stiff shoulder

Age >70 years old

Massive rotator cuff tears: technique of arthroscopic margin convergence

A. Vidil - Paris

1. Definition and biomechanical action

The technique of arthroscopic margin convergence has been reported by S. Burkhart in 1993, knowing that a rotator cuff has a similar configuration to a suspension bridge and can be modeled after the loaded cable of the bridge. The free margin of the tear corresponds to the cable, and the anterior and posterior attachments of the tear correspond to the supports at each end at the cable's span. Burkhart defined a biomechanical integrity of the cuff : despite tendon lesions, shoulder function can be maintained if the anterior and posterior cables are preserved.

In massive rotator cuff tears, partial side-to-side repair causes a margin convergence of the tear toward the greater tuberosity and restore the biomechanical cables of the cuff.

2. Technology implementation

The first step in approaching massive rotator cuff tears is recognizing the pattern of the tear : crescent-shaped tears, U-shaped tears, L-shaped and reverse L-shaped tears, massive contracted immobile tears. To allow complete visualization, all fibro-fatty and bursal tissue must be removed from the margin of the tear. Cuff mobilization can be assessed by dissection of superficial and deep part of the tendon, to allow side to side closure. The converged rotator cuff margin is then repaired to bone with anchors. A medialized simple row repair can be used in case of massive contracted tear and tenotomized biceps tendon can be used as interposition to complete repair to the greater tuberosity.

After surgery, the patient is placed in a sling for 6 weeks and only shoulder passive motion is allowed. Active motion is begun after 6 weeks and strengthening at 3 months postoperatively.

3. Indications

Age: This technique of arthroscopic margin convergence is indicated in massive rotator cuff tears, with stage 3 or 4 fatty degeneration, according to the Goutallier scale. It concerns old patients (average 65 years old) for whom arthroscopic debridement and biceps tenotomy were proposed.

Functional results are correlated with tendon healing, that is often obtained in patients older than 70 years old, as reported in recent literature.

General health patient conditions: A patient's motivation is required to accept immobilization and postoperative care. Transitory handicap can alter a patient's willingness.

Motivation: Functional improvement is reported in all series with a gain in anterior elevation and external rotation, allowing significant pain relief corresponding to 86 % of good or excellent subjective results.

Tendons retraction and fatty infiltration: Functional results are correlated to preoperative fatty infiltration of the cuff. Burkhart et al. reported in 2007 that arthroscopic rotator cuff repair in patients with grade 3 or 4 fatty degeneration (> 50 %) can provide significant functional improvement. Those with 50 to 75 % fatty degeneration showed a much greater degree of improvement than those with > 75 % fatty degeneration. However, clinical improvement was achieved even in 2 of 5 patients with advanced stage 4 involvement.

4. Contraindications

Relatives: glenohumeral joint stiffness, massive rotator cuff tear with advanced stage 4 fatty degeneration

Absolutes: clinical or radiographic excentration of the humeral head, glenohumeral arthritis

5. Expected results

Isolated Supraspinatus / Infraspinatus tear: Functional results are correlated with tendon healing. Clinical improvement will be greater than arthroscopic debridement and biceps tenotomy. If recurring cuff tear occurs, functional gain remains and size of the re-tear seems to be stabilized.

Associated involvement of the Subscapularis (upper part or more) : Partial or complete lesion of the subscapularis must be repaired to restore the anterior cable of the cuff. Its reinsertion on lesser tuberosity is performed by arthroscopic technique.

Associated involvement of the Teres minor: Complete tear of the supraspinatus with posterior extension to include the infraspinatus and teres minor disrupts the coronal and transverse plane force couples. Due to clinical excentration of the humeral head, patients are unable to elevate the affected arm. Teres minor lesion transformed massive rotator cuff tear in an irreparable tear, and technique of arthroscopic margin convergence can no longer be carried out. Only palliative treatment can be proposed, as debridement, biceps tenotomy or partial repair.

The debate: Massive rotator cuff tear: arthroscopic assisted Latissimus Dorsi (LD) transfer

Jean Kany, Clinique de l'Union, Toulouse, France

1 / Definition and LD transfer biomechanic action

A tendon transfer must respect five rules: (1) excursion long enough, (2) direct route, (3) optimal muscle belly tension, (4) strong fixation as close as possible to the centre of rotation of the joint, and (5) agonist of the replaced muscle.

The LD respects 4 of these 5 rules: it is therefore one of the best transfers available, but one transfer cannot alone fully replace two or three deficient tendons (Supraspinatus, Infraspinatus and Teres minor).

2 / Technology implementation (short video)

3 / Indications

Age: Although the time required for cortical integration of tendon transfer to take over is better among younger people there is no age limit. This LD transfer brings less pain and improves function but does not give normal force. Most elderly people (78 years for the oldest one) are more satisfied than younger people (50 years for the youngest one) who are eager to strength recovery too.

General health patient conditions: this is a mini invasive procedure, assisted by arthroscopy. Its average time is around 60 minutes. The only complication remains an axillary hematoma that requires careful coagulation. We recommend supine decubitus position, although this procedure can be routinely performed in beach chair.

Motivation: There is a dramatic and almost immediate pain relief after the surgery because of the "static transfer tenodesis effect" probably. But the "dynamic transfer effect" will take time: 6 to 12 months. Some patients require a 2-year rehabilitation, time required to "cortical integration" take over.

Tendons degree retraction muscle belly trophicity (fatty infiltration): the ideal indication remains a type 3 tendon retraction (beyond the glenoid) with a type 3 or 4 muscle belly fatty infiltration (more fat than muscle).

4 / Contraindications

Relatives: Partial Subscapularis tear
Hamada classification stage 3

Absolute: Complete and irreparable Subscapularis tear
Hamada classification stage 4 or 5 (eccentric shoulder arthrosis)
Pseudo-paralytic shoulder
Axillary nerve palsy (no deltoid)

5 / Expected Results

Isolated Supraspinatus / Infraspinatus tear: here is the best indication to get a minimum of 65/100 Constant score points. Almost complete pain disappearance and function recovery, but unfortunately incomplete strength recovery.

Associated involvement of Teres minor: possible recovery of external rotation but incomplete and without real power.

Associated involvement of the Subscapularis (upper part or more): it is imperative to repair the subscapularis in order to restore the proper horizontal balance with Subscapularis forward, and LD back. Without any Subscapularis, the transferred LD subluxes the humeral head (HH) "up and forward" and increases superior HH escape.

Clinical and electrophysiological results of Latissimus dorsi tendon transfer for irreparable posterosuperior cuff rupture

Julia Bouchaïb, Philippe Clavert - Strasbourg

Introduction

The purpose of this retrospective study is to validate clinical and radiological results latissimus dorsi tendon (LDT) transfer and to determine electrophysiological activities of the transfer for different motions i.e. is it an active transfer?

Material and Methods

With a mean follow-up was 4.7 years, 15 latissimus dorsi tendon transfer performed between 2000 and 2008 (10 men and 4 women) were retrospectively reviewed. Patients' mean age was 52 years.

Patients were clinically evaluated with the constant score, and the SSV. Progress of degenerative osteoarthritis and decreases of the subacromial space were analyzed on plain X-rays. Healing of the tendon on the greater tuberosity was estimated with ultrasound study. The atrophy of the LDT muscle was checked on ct-scan and compared with the controlateral side. The electric activity was analyzed by electromyography in active elevation, abduction and rotations.

Results

patients are satisfied. At the last follow-up, the average pain according to the EVA was 31/100, the strength of 2,5 kg abduction and in rotation extern. The mean Constant score increased from 29 to 51, the mean forward elevation increased from 89 ° to 135 °, the mean abduction from 92 ° to 105 °, and the external rotation from 12 ° to 24°. X-rays find an evolution of the degenerative osteoarthritis, and a decrease of the subacromial space of 2,5 mm. The ultrasound finds 12 healed tendons, 1 uncertain and 2 rupture at the myotendinous junction. We noted a slight atrophy of the muscle transferred with a cross section of 1496 mm² compared to 1713 (controlateral). The EMG found a significant electric activity of the transferred muscle in abduction and external rotation, and a lower activity in adduction and internal rotation.

Discussion and conclusion

Our clinical results are comparable those already published. The electric activity in abduction and external rotation testifies that the LDT transfer is an active muscle transfer and acts not only a muscle tenodesis that covers the humeral head.

Place of the transfer of the Teres Major in extensive ruptures of the rotator cuff

Bellumore Y, Combes JM, M Mansat - Toulouse

The failure of the functional treatment of an irreparable rupture of the posterior superior rotator cuff of the patients of less than 60 years, justify the recourse to a surgery of muscular transfer; the feasibility of the transfer of the tendon of the muscle Teres Major on the greater tuberosity confirmed by anatomical work completed in the service (1), was at the origin of a study whose we reported the long-term clinical experience in 2006 (2).

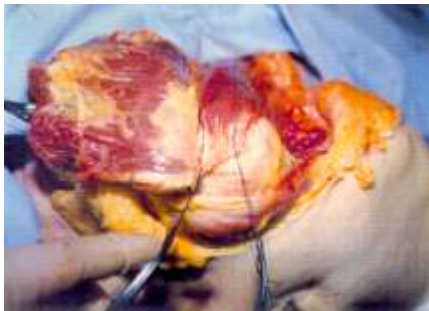


fig. 1 : anatomical works (thesis of JM Combes)

Materials and Methods

This series comprised 14 patients operated between December 1992 and December 2005 with a mean follow-up of 6.6 years. (1-13 years).

There were 3 women and 11 men, average age at surgery was 48 years. Those patients who had essentially a posterosuperior tear of the rotator cuff (3 infraspinatus and 11 supra and infraspinatus lesion) with advanced fatty degeneration (Goutallier > stage 2), were assessed clinically (Constant Score), radiologically and for the majority by a MRI and an electromyography. In 9 cases, it was a surgical revision. We excluded one patient lost to follow-up.

Results

We noted an improvement in the Constant score in all cases, with an average gain of 21.4 points without complication in this short series but we performed a hemiarthroplasty for a failure of the procedure, 6 years after.

These patients found indolent elevation but with a weakness and an active external rotation deficit (+13°).

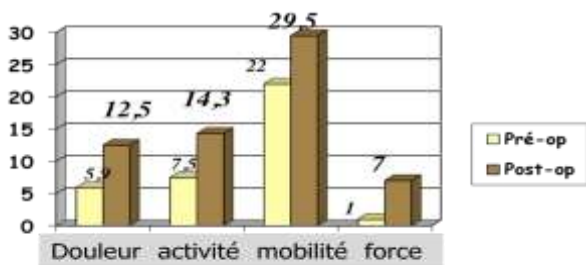


fig. 2 : Constant score

We confirmed the functionality of transfers on MRI and EMG performed.

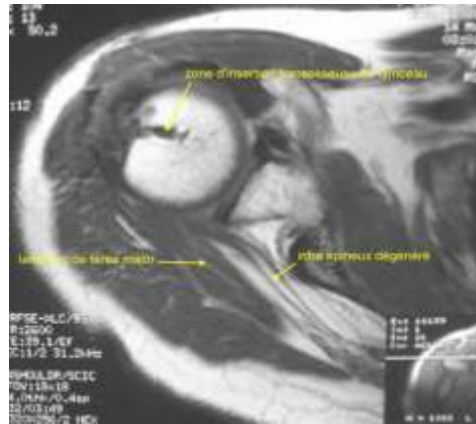

fig 3 : activity on electromyography and MRI findings

However, we did not in any case be able to recenter the upward migration of humeral head on a sensitized radiographic assessment, and the prior favourable results deteriorated into 6 to 9 years with progression to excentered osteoarthritis (Hamada 4).

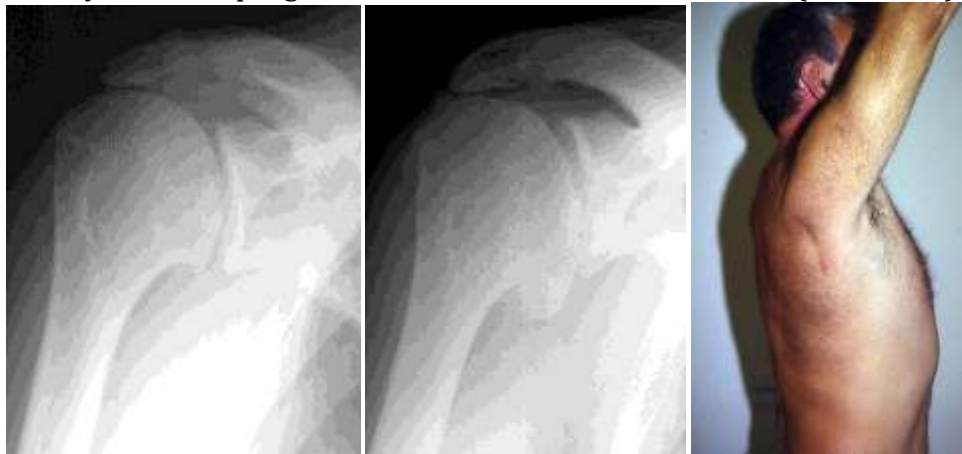


fig 4 : progression to osteoarthritis (1993 TM transfer and 2004 late result)

The worst results concerned multi-operated patients, preoperative osteoarthritis and narrowing of the acromiohumeral space, Teres Minor injury and the upper insertion of the flap on the footprint.

Discussion

This work confirms that this logical (3) transfer is active and not only acts by tenodesis effect.

The best results concern patients with advanced isolated degeneration from the infraspinatus, having a functional Subscapularis and Teres Minor. The purpose of the transfer is to overcome the failing of muscle function: it is less powerful than the original muscle and it is unrealistic to supply the posterior cuff by only Teres Major transfer. The best fixation according to Herzberg (4) is posterior on infraspinatus tendon to avoid traction on its pedicle that promoting a gradual degeneration of the transfer and a re-rupture of the superior tendon attachment (5). Thus a higher posterosuperior rupture requires probably a double transfer (latissimus dorsi + teres major).

Conclusion

We reserve the transfer of teres major to the patients under the age of 60, motivated and compliant, which have a painful and deficit shoulder, with an irreparable rupture of the infraspinatus. It does not prevent progression to osteoarthritic changes and it do not restore a real active external rotation (6, 7, 8, 9, 10 11) but improves the daily activity living of ours patients.

Bibliography

- 1- Combes JM, Mansat M (1993) Lambeau du muscle grand rond dans les ruptures massives de la coiffe des rotateurs. Etude expérimentale. In: «L'Épaule» de Bonnel F, Blotman F, Mansat M, Editeurs. Paris: Springer—Verlag France: 318–330
- 2- Bellumore Y, Dotzis A, Mansat P, Bonnevielle P, Mansat M
Place du lambeau de Teres Major dans les ruptures étendues de la coiffe des rotateurs
Rev. Chir. Orthop. 2006, 92, 3S25-3S3)
- 3- Steenbrink F1, Nelissen RG, Meskers CG, van de Sande MA, Rozing PM, de Groot JH.
Teres major muscle activation relates to clinical outcome in tendon transfer surgery.
Clin Biomech (Bristol, Avon). 2010 Mar;25(3):187-93.
- 4- Anatomical basis of latissimus dorsi and teres major transfers in rotator cuff tear surgery with particular reference to the neurovascular pedicles.
Schoierer O, Herzberg G, Berthonnaud E, Dimnet J, Aswad R, Morin A.
Surg Radiol Anat. 2001;23(2):75-80.
- 5- Ling HY, Angeles JG, Horodyski MB.
Biomechanics of latissimus dorsi transfer for irreparable posterosuperior rotator cuff tears.
Clin Biomech (Bristol, Avon). 2009 Mar;24(3):261-6
- 6- Gerber C1, Rahm SA, Catanzaro S, Farshad M, Moor BK.
Latissimus dorsi tendon transfer for treatment of irreparable posterosuperior rotator cuff tears: long-term results at a minimum follow-up of ten years.
J Bone Joint Surg Am. 2013 Nov 6;95(21):1920-6.
- 7- Gerber C1, Maquieira G, Espinosa N.
Latissimus dorsi transfer for the treatment of irreparable rotator cuff tears.
J Bone Joint Surg Am. 2006 Jan;88(1):113-20.
- 8- Namdari S, Voleti P, Baldwin K, Glaser D, Huffman GR.
Latissimus dorsi tendon transfer for irreparable rotator cuff tears: a systematic review.
J Bone Joint Surg Am. 2012 May 16;94(10):891-8.
- 9- Celli L, Rovesta C, Marongiu MC, Manzieri S.
Transplantation of teres major muscle for infraspinatus muscle in irreparable rotator cuff tears.
J Shoulder Elbow Surg. 1998 Sep-Oct;7(5):485-90.
- 10- Habermeyer P1, Magosch P, Rudolph T, Lichtenberg S, Liem D
Transfer of the tendon of latissimus dorsi for the treatment of massive tears of the rotator cuff: a new single-incision technique.
J Bone Joint Surg Br. 2006 Feb;88(2):208-12.
- 11- Aldridge JM, Atkinson TS, Mallon WJ
Combined pectoralis major and latissimus dorsi tendon transfer for massive rotator cuff deficiency.
J Shoulder Elbow Surg. 2004 Nov-Dec;13(6):621-9.

L'Episcopo-Sever and RSA

L'Episcopo-Sever procedure A trip in the past

Denis Katz - Lorient

Latissimus dorsi with or without teres major transfer, is the most commonly reported tendon transfer to the shoulder.

1) The initial indication was for brachial plexus paralysis.

The story started in 1874 when the Erb's paralysis (or Erb-Duchenne) has been described, the main cause being obstetrical accident. The sequellae of such a paralysis of C5-C6 is a persistent internal rotation contracture of the shoulder with inability to abduct the arm. In such a situation, in 1918 James Sever (1878-1964) proposed to cut the pectoralis major and subscapularis tendon.

In 1934 Joseph B L'Episcopo (1890-1947) noted a frequent recurrence of the deformation. In order to correct the lack of elevation and lateral rotation, He added to the Sever release a transfer of of latissimus Dorsi and Teres major around the humerus and fixed together under a periosteal flap (1).

A lot of publications until today related the results of this operation, which have been modified by several authors such as Hoffer in 1978(2) who proposed to add a posterior approach and Alain Gilbert in 1982 who transfers only the latissimus dorsi .

2) In 1988 Christian Gerber was the first to extend the indications to the treatment of massive cuff tears(3) .

Since this time a lot of debates arose about technical or indications problems :

-Do we need to transfer both Latissimus Dorsi and teres major ?

Some are favorable such as Henry (4), Herzberg (5) or Lichtenberg (6) arguing that the TM tendon is bulky and less capable of excursion. Hartzler published a biomechanical study of the external rotation moment arm, comparing the effectiveness of the lower trapezius transfer, the latissimus dorsi and/or the teres major on the recovery of external rotation, at various degrees of abduction.(7)The lat dorsi and teres major transfer are more efficient at 90° of abduction.

-where must we fix the tendons ?

In a finite element model studies, Magermans(8-9) showed that transferring the LD tendon to the supraspinatus insertion is less favorable to restore biomechanical conditions of the normal shoulder than transferring the LD tendon to the infraspinatus insertion .

-Is the subscapularis rupture a contraindication ?

Gerber's team(10)conducted a biomechanical study which showed that a LD tendon transfer after a complete subscapularis tear was responsible for a great imbalance of the shoulder joint with anterior dislocation forces .

As a conclusion, all authors agreed that :

a)A complete or irreparable subscapularis tears was a definitive contraindication for a LD transfer.

b) A partial and repaired subscapularis tear had no negative influence on the results.

Gerber published one of the most complete and long term study about this transfer (11)

3) The increasing indications of **reverse shoulder arthroplasty**, introduced the idea of adding to the arthroplastic procedure, a L'Episcopo transfer in case of horn blower sign, which is not well corrected by a standard reverse (12,13,14,15).

4) arthroscopy :

The most recent advent is the capability of doing the transfer arthroscopically (16,17,18,19). There are not many publications about clinical results, among them 2 have to be outlined (20,21)

5) subscapularis reconstruction

Finally a recent article of Elhassan studied the feasibility of the latissimus dorsi and teres major transfer to reconstruct irreparable subscapularis tendon tear. (22)

BIBLIOGRAPHY :

- 1- **L'Episcopo JB**. Tendon transplantation in obstetrical paralysis. *Am J Surg.* 1934;25:122-5
- 2- **Hoffer MM, Wickenden R, Roper B**. Brachial plexus birth palsies. Results of tendon transfer to the rotator cuff. *J Bone Joint Surg Am.* 1978;60:691-4.
- 3- **Gerber C, Vinh TS, Hertel R, Hess CW**. Latissimus dorsi transfer for the treatment of massive tears of the rotator cuff. A preliminary report. *Clin Orthop Relat Res.* 1988;232:51-61
- 4- **Henry PDG, Dwyer T, MacKee MD, Schemitsch EH**. Latissimus dorsi tendon transfer for irreparable tears of the rotator cuff. An anatomical study to assess the neurovascular hazards and ways of improving tendon excursion. *J Bone Joint Surg Br.* 2013;95:517-22.
- 5- **Hertzberg G, Urien JP, Dimnet J**. Potential excursion and relative tension of muscles in the shoulder girdle: relevance to tendon transfers. *J Shoulder Elb Surg.* 1999;8:430-7
- 6- **Lichtenberg S, Magoch P, Habermeyer P**. Are there advantages of the combined latissimus dorsi transfer according to L'Episcopo compared with the isolated latissimus dorsi transfer according to Hertzberg after a mean follow-up of 6 years? A matched-pair analysis. *J Shoulder Elb Surg.* 2012;21:1499-507.
- 7- **Hartzler RU, Barlow JD, MD, Kai-Nan An, Elhassan BT** : Biomechanical effectiveness of different types of tendon transfers to the shoulder for external rotation *J Shoulder Elbow Surg (2012) 21, 1370-1376*
- 8- **Magermans DJ, Chadwick EKJ, Veeger HEJ, Rozing PM, Van der Helm FCT**. Effectiveness of tendon transfers for massive rotator cuff tears: a simulation study. *Clin Biomech.* 2004;19:116-22.
- 9- **Magermans DJ, Chadwick EKJ, Veeger HEJ, Van der Helm FCT, Rozing PM**. Biomechanical analysis of tendon transfers for massive rotator cuff tears. *Clin Biomech.* 2004;19:350-7.
- 10- **Gerber C, Maquieira G, Espinosa N**. Latissimus dorsi transfer for the treatment of irreparable rotator cuff tears. *J Bone Joint Surg Am.* 2006;88:113-20
- 11- **Gerber C, Maquieira G, Espinosa N**. Latissimus dorsi transfer for the treatment of irreparable rotator cuff tears. *J Bone Joint Surg Am.* 2006;88:113-20
- 12- **Gerber C, Pennington SD, Lingenfelter EJ, Sukthankar A**. Reverse Delta-III total shoulder replacement combined with latissimus dorsi transfer. A preliminary report. *J Bone Joint Surg Am.* 2007;89:940-947. doi: 10.2106/JBJS.F.00955.

- 13-**Boileau P, Chuinard C, Roussane Y, Bicknell RT, Rochet N, Trojani C.** Reverse shoulder arthroplasty combined with a modified latissimus dorsi and teres major tendon transfer for shoulder pseudoparalysis associated with dropping arm. *Clin Orthop Relat Res.* 2008;466:584-93.
- 14- **Boughebri O, Kilinc A, Valenti P.** Reverse shoulder arthroplasty combined with a latissimus dorsi and teres major transfer for a deficit of both active elevation and external rotation. Results of 15 cases with a minimum of 2 year follow-up. *Orthop Traumatol Surg Res.* 2013;99:131-7.
- 15-**Puskas GJ, Catanzaro S, Gerber C.** Clinical outcome of reverse total shoulder arthroplasty combined with latissimus dorsi transfer for the treatment of chronic combined pseudoparesis of elevation and external rotation of the shoulder. *J Should Elb Surg.* 2013;22:1395-9.
- 16-**Gervasi E, Causero A, Parodi PC, Raimondo D, Tancredi G.** Arthroscopic latissimus dorsi transfer. *Arthroscopy.* 2007;23(1243):e1-4.
- 17- **Millett PJ, Yen YM, Huang MJ.** Arthroscopically assisted latissimus dorsi transfer for irreparable rotator cuff tears. *Tech Should Elbow Surg.* 2008;9:76-9.
- 18- **Kany J, Kumar HA, Chang VK, Grimberg J, Garret J, Valenti P.** Mini invasive axillary approach and arthroscopic humeral head interference screw fixation for latissimus dorsi transfer in massive and irreparable postero-superior rotator cuff tears. *Tech Should Elbow Surg.* 2010;11:8-14.
- 19-**Goldstein Y, Grimberg J, Valenti P, Chechik O, Drexler M, Kany J.** Arthroscopic fixation with a minimally invasive axillary approach for latissimus dorsi transfer using an endobutton in massive and irreparable postero-superior cuff tears. *Int J Shoulder Surg.* 2013;7:79-82.
- 20-**Villacis D, Merriman J, Wong K, Hatch III GFR.** Latissimus dorsi transfer for irreparable rotator cuff tears: a modified technique using arthroscopy. *Arthrosc Tech.* 2013;1:e27-30.
- 21- Grimberg J , Kany J :Latissimus dorsi tendon transfer for irreparable postero-superior cuff tears: current concepts, indications, and recent advances . *Curr Rev Musculoskelet Med* DOI 10.1007/s12178-013-9196-5
- 22- **Elhassan B, MD, Christensen TJ, MD, Wagner ER, MD**
Feasibility of latissimus and teres major transfer to reconstruct irreparable subscapularis tendon tear: an anatomic study *J Shoulder Elbow Surg* (2013) -, 1-8

Complications and Risks : L'Episcopo Sever and RSA.

What are the risks of the l'Episcopo's palliative transfer or similar?

Régis Guinand – St Jean / Toulouse

The literature reports few cases of complications from different techniques (posterior approach according to Beauchamp (1) or Herzberg (2), deltopectoral approach to Boileau (3) and Boughrebi(4)); taken only Latissimus Dorsi (LD) , Teres major (TM) or both ... and varied fixation technics (anchors, trans -osseous) .

The main risk is neurological due to the proximity of the radial nerve in relation with LD and TM tendons, but also the axillary nerve in the quadrilateral space whose LD and TM tendons are the distal limit (Strecker (5)).

The second risk regularly cited in the literature is the failure of the tendon attachment to the humerus , which occurred so much with anchors or transosseous fixations, causing a lack of palliative effect on the external rotation (Boileau (6), Gerhardt (7), Covey (8)).

Do we find in the literature specific complications during combined surgery of RSA and l'Episcopo Sever tendon transfer?

According to Puskas (9) , who recently published a very precise serie in terms of complications , there is no specific complications (apart from those mentioned above) but the co- morbidities promote the development of “orthopedic” complications (positional neurological stretching, level supports, cardiopulmonary complications ...) .

The combination of a prosthesis and tendon transfer completion does not seem to significantly increase the rate of infection.

(1) Functional outcome after the L'Episcopo procedure.

Beauchamp M, Beaton DE, Barnhill TA, Mackay M, Richards RR.

J Shoulder Elbow Surg. 1998 Mar-Apr;7(2):90-6.

(2) Potential excursion and relative tension of muscles in the shoulder girdle : relevance to tendon transfers.

Herzberg G, Urien JP, Dimnet J.

J Shoulder Elbow Surg. 1999;8 :430-437.

(3) Modified latissimus dorsi and teres major transfer through a single delto-pectoral approach for external rotation deficit of the shoulder: as an isolated procedure or with a reverse arthroplasty.

Boileau P, Chuinard C, Roussanne Y, Neyton L, Trojani C.

J Shoulder Elbow Surg. 2007 Nov-Dec;16(6):671-82.

4) Reverse shoulder arthroplasty combine with a latissimus dorsi end teres major transfer for a deficit of both active elevation and external rotation.Results of 15 cases with a minimum of 2 year follow-up. **O.**

Boughrebi, A Kilinc, P. Valenti.

Orthop Traumatol Surg Res. 2013 Apr; 99(2):131-7. doi: 10.1016/j.otsr.2012.11.014. Epub 2013 Mar 17

(5) Sever-L'Episcopo transfers in obstetrical palsy: a retrospective review of twenty cases.

Strecker WB, McAllister JW, Manske PR, Schoenecker PL, Dailey LA.

J Pediatr Orthop. 1990 Jul-Aug;10(4):442-4.

(6) Reversed shoulder arthroplasty with modified L'Episcopo for combined loss of active elevation and external rotation.

Boileau P, Rumian AP, Zumstein MA.

J Shoulder Elbow Surg. 2010 Mar;19(2 Suppl):20-30.

(7) Modification of the L'Episcopo procedure for brachial plexus birth palsies.

Covey DC, Riordan DC, Milstead ME, Albright JA.

J Bone Joint Surg Br. 1992 Nov;74(6):897-901.

(8) Modified L'Episcopo tendon transfers for irreparable rotator cuff tears: 5-year follow-up.

Gerhardt C, Lehmann L, Lichtenberg S, Magosch P, Habermeyer P.

Clin Orthop Relat Res. 2010 Jun; 468(6):1572-7.

(9) Clinical outcome of reverse total shoulder arthroplasty combined with latissimus dorsi transfer for the treatment of chronic combined pseudoparesis of elevation and external rotation of the shoulder.

Puskas GJ, Catanzaro S, Gerber C.

J Shoulder Elbow Surg. 2014 Jan;23(1):49-57

RSA and Modified Episcopo Procedure

Nicolas Bonneville, Pascal Boileau
Nice, France

Introduction

Combined loss of active elevation and external rotation is a debilitating situation for most of patient. At short and medium follow-up, previous studies reported satisfactory results after reverse shoulder arthroplasties combined with latissimus dorsi/Teres major transfert (L'Episcopo procedure). **(Figure 1)**

Aim

Evaluation of subjective and objective outcomes in a large cohort of patients and to validate if postoperative improvement passes the test of time.

Patients and Methods

From 2004 to 2011, 36 patients were consecutively treated for Combined Loss of active Elevation and External Rotation (CLEER) with a RSA and a latissimus dorsi/Teres major transfert (L'Episcopo). Clinical outcomes and radiographic analysis were investigated prospectively with a mean follow-up of 44,2 months (range : 12—92).

Results

The mean age of patients was 72 years (range;55-84). The SSV score significantly increase from 28% preoperatively to 74% at follow-up. The mean gain of active anterior elevation and external rotation was respectively 65°and 28°. The ADLER score and Constant score reached 24 points and 64 points at follow-up. All but two patients were satisfied or very satisfied. **(table 1)**

Conclusion

The use of RSA combined with a modified L'Episcopo transfert is a valuable procedure to treat CLEER. The subjective and objective evaluation showed that the improvement passed the test of time.

Figure 1

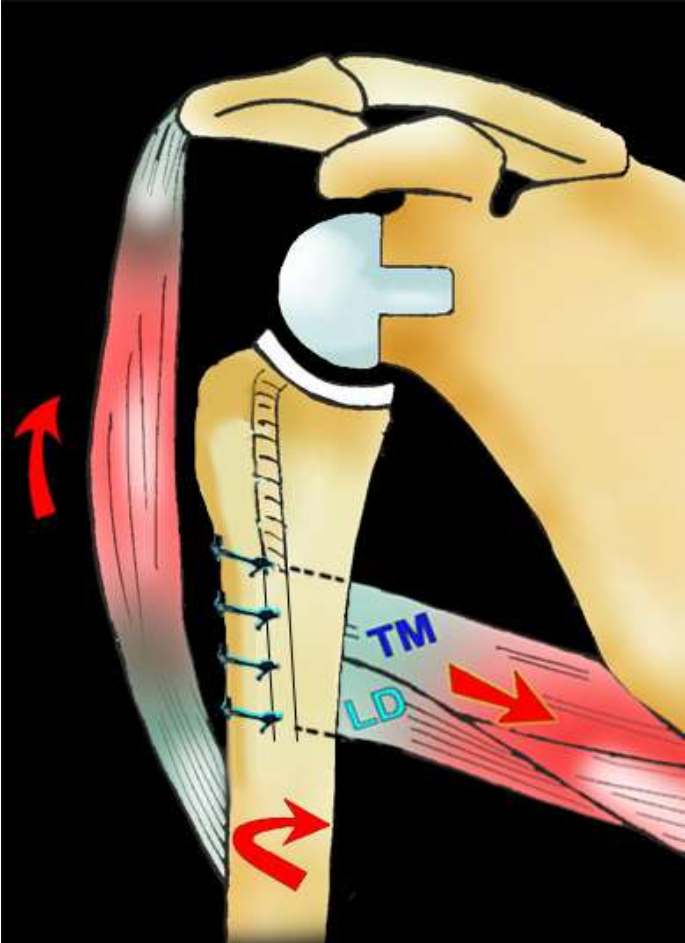


Table 1

	PREOP	POSTOP
Pain	5.9	12.9
Activity	5.4	15.7
Mobility	14.7	26.4
Strength	1.1	9.4
CS TOTAL	27.2	64.4
AAE	72	139
ER	-24	4
IR	6	3.6
ADLER	5.0	23.8
SSV	23%	77%

Inferior trapezium

Low trapezius transfer for shoulder abduction rehabilitation : a cadaveric feasibility study

L. Bourcheix * # ; S. Guéro *

* Institut de Chirurgie de la Main, 5 rue du Dome, Paris 75116

École de chirurgie, 7 rue du Fer Moulin , 75221 Paris Cedex 05

We present an anatomical study using an original technique of transfer of the low trapezius muscle on the shaft of the ipsilateral humerus.

Materials and Methods: 40 specimens from 20 fresh cadavers were studied using two separate and conjoint procedures:

1) Dissection of the ascending beams and transfer of the trapezius muscle on the lateral aspect of the proximal part of the humeral shaft. The mobilization of muscle bundle is performed after collapse of vertebral spinal muscular attachments from T4 to T11- 12 associated , at its lower end , a removal of a strip of thoraco- lumbar fascia 2 cm. Inserts on the spine of the scapula are met. The technique continues with a tunneling in the pit and above spinal fixation with an anchor end of the transfer to the side of the humerus , the next V deltoïd .

2) Injection colorful silicone RTV designed for the study of the vascularization of transverse beams and bottom of the trapezius muscle . Injection performed in sub- subclavian artery and the external jugular veins and transverse cervical.

3 protocols have been established:

1) For 5 subjects (10 trapezoids) only the first procedure .

2) For 5 subjects (10 trapezoids) , the second procedure followed the first .

3) For 10 subjects (20 trapezoids) , the first procedure followed by the second and finalized by the revelation of the injection by complete dissection of muscle transfer .

Results: the bottom beam of the trapezius muscle in the form of a triangle to upper base , the spinal side of the triangle was measured from 21.5 to × 23.7 cm (average 22.3 cm) in these figures must be added 2 cm strip of thoraco- lumbar fascia . The distance between the apex of the spinous process of T3 in the rough deltoïd crest of the humerus was measured from 23.5 to 25 cm (average 24), shoulder placed in neutral position. The point of rotation of this transfer is at the medial end of the spine of the scapula. The removal of a tongue thoraco- lumbar fascia (superficial lamina) has allowed each mooring transfer in the surgical neck of the humerus ipsilateral . Vascular study allowed us to visualize the transverse cervical pedicle (artery and vein) and a common pedicle rhomboid major muscle and the trapezius branch of the scapular pedicle higher. On two occasions, we found an injection failure due to a technical fault. During the 3rd protocol for 9 subjects, we observed a complete injection of the two arteriovenous pedicle.

Conclusion : The transfer of the beam bottom of the trapezius muscle is perfectly feasible anatomically without impeding a major way contenance two major vascular pedicle .

Keywords: Shoulder, trapezius palsy.

Biomechanical basis of lower trapezius transfer

A. Vidil - Paris

Tendon transfer is one treatment option for patients with massive irreparable rotator cuff tears. The biomechanical rationale is to restore the glenohumeral joint force couple, and the potential benefits include pain relief and increased strength.

Latissimus dorsi, with or without teres major transfer, is the most commonly reported tendon transfer in patients with massive posterosuperior rotator cuff tears. Its goal is to exert an external rotation force that allows for a more balanced state in the glenohumeral joint, and replaces the function of the posterior force couple. However, the line of pull of the latissimus dorsi transfer is more vertical than that of the native posterior cuff, which may explain the varied results in restoring external rotation.

Lower trapezius transfer seems to be better situated to have a more direct line of pull to improve external rotation. Anatomically, the force vector of this transfer is more in line with the physiologic pull of the native rotator cuff. A recent cadaver biomechanical study compared the effectiveness of latissimus dorsi, teres major and lower trapezius transfers for shoulder external rotation, by determining the external rotation moment arm (ERMA) of each muscle transferred to selected locations on the humerus.

With the arm at the side, the lower trapezius muscle has adequate excursion and tension to replace the function of the infraspinatus. In this position, the ERMA of the lower trapezius is almost similar to the anatomic shoulder external rotators and significantly higher than the latissimus dorsi and the teres major. The difference is potentially explained by the direction of pull of the latissimus dorsi, that is much more parallel to the axis of rotation compared with the direction of pull of the lower trapezius and teres major. The lower trapezius transfer is best indicated in patients where shoulder external rotation is performed mainly with the arm functioning at the side of the body.

With the humerus in 90° of abduction, there is a significant increase in the ERMA of the latissimus dorsi transfer, a significant decrease in the ERMA of the lower trapezius transfer, and no changes in the ERMA of the teres major transfer, compared with the arm-at-side position. With the arm abducted, the line of pull of latissimus dorsi becomes perpendicular to the axis of rotation, a more favorable position for producing an external rotation moment, whereas the line of pull for the lower trapezius becomes more parallel to the axis of rotation. The teres major has a relatively constant ERMA with the change in position of the humerus, which is consistent with the line of pull intermediate to lower trapezius and latissimus dorsi. Teres major is an efficient shoulder tendon transfer with the humerus in adduction or abduction; latissimus dorsi transfer can restore external rotation, especially if the shoulder can be abducted, which puts the transfer in a more favorable position to exert an external rotation moment.

In spite of these theoretical advantages, lower trapezius transfer is limited by the fact that an allograft must be used to improve its excursion. Thus, issues related to healing must be taken into account; further biomechanical and clinical studies are necessary before this transfer can be recommended.

INFERIOR TRAPEZIUS TRANSFER FOR THE SHOULDER

literature review

Denis Katz

The lower trapezius flap was first described by Mathes and Nahai in their clinical atlas of myocutaneous flap in 1979, for plastic surgical indications of skin coverage.

The flap can be used as a pedicle or a free flap. It is possible to transfer its medial spinal or its scapular insertion and to use it separately or in combination with the medium and/or superior part of the muscle.

Multiple applications arose for carcinologic surgery, for brachial plexus surgery either in adults or in children and more recently for massive rotator cuff tear indications.

For shoulder surgery in brachial plexus lesions, the trapezius muscle is often functional because innervated by the spinal accessory nerve coming from the 11th cranial nerve. If the spinal accessory nerve has been used for a primary procedure as a graft or for neurotisation, the contralateral muscle can be used and transferred to the involved side. In adults it is often a more global paralysis and the first goal of surgery in this dramatic situation is to reduce the inferior subluxation of the glenohumeral joint and to restore a good flexion of the elbow.

But restauration of active elbow flexion can result in a « hand on belly motion ». In such a situation the hand cannot be functional in use, which is a frustrating situation.

If so, as for rotator cuff tear surgery, the objective of a lower trapezius transfer is to restaure a lateral rotation, in order to help driving the hand in front of the body. A biomechanical study showed that the moment arm for external rotation of the lower trapezius is the best one at 0° of abduction.

For shoulder surgery in massive rotator cuff tear the use of the lower trapezius is recent. To improve the chances of a successful muscle transfer, important principles should be followed.

A transferred muscle should:

- 1) have similar excursion as the recipient muscle,
- 2) have similar tension as the recipient muscle,
- 3) be expendible,
- 4) have at least M4 strength,
- 5) have similar line of pull
- 6) be used for a single purpose: one muscle one function.

In order to restaure the lateral rotation, the trapezius muscle transfer to the infraspinatus matches most of these goals.

But the tendon is not enough long to reach the infraspinatus. The use of allografts or autografts have been described but this is a limitation for a current use, and a risk of increasing some adhesions. Philippe Valenti is working on a new technique of lengthening with a conservation of the periosteal insertion of the lower trapezius on the scapular spine in continuity with a part of the infraspinatus fascia.

It can be fixed to the infraspinatus footprint or in the tendinous multipennated end of the muscle.

For rotator cuff repair, except a recent poster in the last american academy, the literature about a clinical use for the moment is poor.

This topic will try to show that it is a promising procedure.

Lower trapezium transfer: Indications

Philippe VALENTI - Paris

Lower trapezium transfer has been reported to restore active external rotation in brachial plexus lesion C5 C6 .

In postero superior irreparable cuff tear with a dropping sign and an hornblower sign, according to a combined lesion of supra spinatus(SS) , infraspinatus(IS) and the teres minor(Tm) , the Lower trapezium lengthened with an allograft or an autograft(fascia lata/ semi tendinous) and fixed on the IS Footprint can be indicated.

Lower trapezium tendon transfer can be associated with a latissimus dorsi transfer fixed at the level of the insertion of the supra spinatus to the great tuberosity in extensive postero superior tear (SS+IS+Tm).

A poster in AAOS 2014 (Donegan et Al; Washington University) reported the results of 14 lower trapezium tendon transfer for irreparable postero superior cuff tear. An Achille allograft was fixed at the distal part of the lower trapezium, and through a subcutaneous tunnel was fixed in the IS footprint. SS and IS were ruptured with an IS atrophic with a fatty infiltration >3 ; any information regarding the teres minor . With a mean FU 15,9 months(11.5-28), this tendon transfer improve in pain relief and the active motion in elevation and external rotation with more strength in external rotation(50,1 N). The control with ultrasound proved that the transfer was intact in 8/12with a contraction at the EMG study in 12/12. This transfer also improve in pain relief

Erb Palsy

A “Subscapularis-Preserving Arthroscopic Release of Capsule” (“SPARC” procedure) in the treatment of medial rotation contracture of shoulder in Erb’s palsy with @Latissimus Dorsi Transfer

Jean Kany, Clinique de l’Union, Toulouse, France

Background:

Shoulder medial contracture occurs in 25% of children in Erb’s palsy. About one hundred years ago, our masters (1,2,3) introduced the anterior gleno humeral capsular release, and sometimes a Subscapularis tenotomy in addition. 40 years ago, Carlioz (4) described the proximal Subscapularis release directly onto the anterior surface of the scapula.

We used the Carlioz technique for more than 20 years in Toulouse Purpan Pediatric Department of Pr Cahuzac. Children gained a very good activity daily motion. But most parents and children asked questions about the loss of active medial rotation.

We hypothesized that the cause of this complication was the Subscapularis damage, either by its tenotomy (Episcopo/Sever procedure) or by its proximal muscle belly release (Carlioz). We have introduced (5) an arthroscopic procedure to perform an anterior capsular release without any damage onto the Subscapularis tendon or muscle belly in order to prevent any loss of active medial rotation. We call this procedure: “SPARC procedure” (Subscapularis Preserving Arthroscopic Release Capsule). In the same stage, we have made an arthroscopic assisted Latissimus Dorsi (LD) transfer onto the cuff (arthroscopic assisted modified “Hoffer” (6) procedure).

Materials and methods

Within the 1999-2008 period, 16 paediatric shoulders were operated on for medial rotation contracture due to residual Erb’s palsy. The medial rotation contracture was released arthroscopically and Latissimus Dorsi transfer to rotator cuff was performed (modified arthroscopic assisted Hoffer procedure). In case of arthroscopic release failure, classic open Carlioz procedure with LD transfer was carried out. There were 11 unilateral cases involving C5, C6 roots and five cases involving C5, C6 and C7 roots. There were nine boys and seven girls. The average age of the children was 20.2 months (range 10–54 months). Passive external rotation was measured preoperatively and postoperatively with the arm by the side of the body. The Mallet score (7) before surgery and at revision assessed children. The “SPARC” surgical procedure was carried out when the passive external rotation (ER1) was less than or equal to 0°.

Results

The “SPARC” procedure failed for the first two cases in 1998 because of the learning curve. Four other cases had a posterior dislocation of the glenohumeral joint in which the SPARC procedure was not proposed. In those six cases, the classic open Carlioz procedure with LD

transfer were executed and excluded from this series. In the remaining 10 cases, we performed the SPARC procedure. These 10 children were followed up for an average period of 41.5 months (12–59 months). The average preoperative external rotation was -11.51 (0 to -20°), the internal rotation according to Mallet's score was on average 2.3 points and the average abduction and forward flexion was $+62^\circ$ (50 - 90°). In the immediate postoperative period, the passive external rotation was $+65.51$ (60 - 70°), with an average gain of $+77^\circ$ (70 - 90°). On follow-up, the external rotation was $+54.51$ (45 - 80°), internal rotation remained unchanged and the gain in abduction and forward flexion averaged $+150^\circ$ (130 - 170°). No complications were observed in this series. There was no case of recurrence of internal rotation contracture even after 41.5 months follow-up.

Discussion:

In Erb's palsy sequelae, shoulder medial contracture could be caused either by anterior capsular stiffness and/or by Subscapularis muscle belly contracture.

The gleno humeral (GH) capsule is not normal. The disease is neurologic first: muscles are not pathologic alone. Aszmann (9) showed that GH capsular innervation comes from C5 and C6 roots: therefore capsule is pathologic too. So far, there has not been in vivo anatomic pathologic study of the GH capsule in Erb's palsy but "contractil Vimentine like protein" were described in rats, clubfoot, or frozen shoulder. Maybe "Vimentine like" exists in Erb's palsy too. Finally, Neer (10) Ferrari (11), and later Harryman (12) showed the significance of the Rotator Interval (RI), the Coraco Humeral Ligament (CHL) and the Superior Gleno Humeral Ligament (SGHL) in the limitation of External Rotation (ER). As a result, anterior capsular release should be performed.

Is the Subscapularis muscle belly pathologic first? The answer is not clear. Subscapularis innervation comes from each brachial plexus root, not only C5 and C6 roots. So this muscle is not completely paralysed. Einarsson (13) realised Subscapularis muscle belly biopsies in Erb's palsy and compared with normal side. He just found mechanical sarcomeres modifications without any neurologic changes. Furthermore, as the loss of active medial rotation is the main complication after Subscapularis release (either with tenotomy or with proximal muscle belly release), this step does not seem crucial. Pearl (14, 15) also saw this problem, using nevertheless an arthroscopic mini invasive technique with a total Subscapularis tenotomy. Conversely, Kozin (16) preserves the distal part of the Subscapularis tendon using an arthroscopic technique too; and because of that he has never seen any decrease of the active medial rotation.

Isolated anterior GH capsular release is good enough probably if early performed before anatomic substantial joint deformities and before bone and/or cartilage histopathologic changes that appeared at 5 months and on (17, 18).

Arthroscopy should help us for a focused isolated anterior GH capsular release. Difficulties come from learning curve and specific instrumentation. But with experience, it is easier and less invasive than open surgery to see and to assess Harryman's main anatomic structures (RI, CHL and SGHL) like the capsular release key. ER gains were equal to Carlioz classic open technique steady after 4 years FU, without any decrease in active medial rotation.

Conclusion

« Subscapularis Preservation and Arthroscopic Capsular Release » (SPARC procedure) performed early before substantial medial contracture is useful in medial contracture of the shoulder in brachial palsy (as soon as $ER1 \leq 0^\circ$).

References

- 1/ Fairbank HAT. Birth palsy: subluxation of the shoulder-joint in infants and young children. *Lancet* 1913; 1:217–223.
- 2/ Sever JW. The results of a new operation for obstetrical paralysis. *J Bone Joint Surg Am* 1918; 16:248–257.
- 3/ L'Episcopo JB. Tendon transplantation in obstetrical paralysis. *Am J Surg* 1934; 25:122–152.
- 4/ Carlioz H, Brahimi L. Place of internal disinsertion of the subscapularis muscle in the treatment of obstetric paralysis of the upper limb in children [in French]. *Ann Chir Infant* 1971; 12:159–167.
- 5/ Abid A, Kany J, Accadbled F, Darodes P, Knorr G, Sales de Gauzy J, Cahuzac JP. Arthroscopic anterior capsular release in medial contracture of the shoulder secondary to brachial plexus birth palsy. Preliminary results [in French]. *Rev Chir Orth* 2008; 94:643–648.
- 6/ Hoffer MM, Wickenden R, Roper B. Brachial plexus birth palsies. Results of tendon transfers to the rotator cuff. *J Bone Joint Surg Am* 1978; 60: 691–695.
- 7/ Kany J, Kumar HA, Amaravathi RS, Abid A, Accadbled F, de Gauzy JS, et al. A subscapularis-preserving arthroscopic release of capsule in the treatment of internal rotation contracture of shoulder in Erb's palsy (SPARC procedure). *J Pediatr Orthop B*. 2012 Sep; 21(5):469–473. doi:10.1097/BPB.0b013e328353a19f
- 8/ Mallet J. Obstetrical Palsy [in French]. *Rev Chir Orthop* 1972; 58 (Suppl 1):115–200.
- 9/ Aszmann OC1, Dellon AL, Birely BT, McFarland EG. Innervation of the human shoulder joint and its implications for surgery. *Clin Orthop Relat Res*. 1996 Sep;(330): 202-7.
- 10/ Neer CH, Satterlee C, Dalsey R, Flatow E. The anatomy and potential effects of contracture of the coracohumeral ligament. *Clin Orthop Rel Res* 1992; 280:182–185.
- 11/ Ferrari DA. Capsular ligaments of the shoulder. Anatomical and functional study of the anterior superior capsule. *Am J Sports Med* 1990; 18:20–24. 25
- 12/ Harryman DT, Sidles JA, Harris SL, Matsen FA. The role of the rotator interval capsule in passive motion and stability of the shoulder. *J Bone Joint Surg (Am)* 1992; 74:53–66.

13/ Einarsson F, Hultgren T, Ljung B-O, Runesson E., Friden. Subscapularis Muscle Mechanics in Children with Obstetric Brachial Plexus Palsy. *J Hand Surg (Eur)* 33, 4 : 507-512 (2008)

14/ Pearl ML. Arthroscopic release of shoulder contracture secondary to birth palsy: an early report on findings and surgical technique. *Arthroscopy* 2003; 19:577-582.

15/ Pearl ML, Edgerton BW, Kazimiroff PA, Burchette RJ, Wong K. Arthroscopic release and Latissimus dorsi transfer for shoulder internal rotation contractures and glenohumeral deformity secondary to brachial plexus birth palsy. *J Bone Joint Surg Am* 2006; 88:564-574.

16/ Kozin SH, Boardman MJ, Chafetz RS, Williams GR, Hanlon A. Arthroscopic treatment of internal rotation contracture and glenohumeral dysplasia in children with brachial plexus birth palsy. *J Shoulder Elbow Surg* 2010; 19:102-110.

17/ Pearl ML, Edgerton BW. Glenoid deformity secondary to brachial plexus birth palsy. *J Bone Joint Surg Am* 1998; 80:659-667.

18/ Kozin SH. Correlation between external rotation of the glenohumeral joint and deformity after brachial plexus birth palsy. *J Pediatr Orthop* 2004; 24:189-193.

Arthroscopic release for shoulder internal rotation contracture secondary to brachial plexus birth palsy

Clinical and MRI results.

Abdelaziz Abid (MD), Jean Kany (MD), Franck Accadbled (MD, PhD), Jérôme Sales de Gauzy (MD), Jean Philippe Cahuzac (MD)

from:

Department of Paediatric Orthopaedic Surgery, Hôpital des Enfants, CHU de Toulouse, France

Purpose

Internal rotation contracture occurs in 25% of patients with high brachial plexus birth palsy (C5, C6, + /- C7). This frequently leads to early shoulder dysplasia and impaired function. Treatment relies on surgical release which can involve the anterior capsule and ligaments or the subscapularis or both. Latissimus dorsi transfer may be combined to restore active external rotation. We evaluated clinical and MRI results of arthroscopic release sparing the subscapularis associated with latissimus dorsi transfer.

Methods

Six children (mean age 22.8 months old, range 14 to 54) were referred for internal rotation contracture of the shoulder. All had recovered biceps brachialis function within the first 6 months of life. They were operated on with shoulder anterior arthroscopic release sparing the subscapularis associated with latissimus dorsi transfer. Clinical examination and MRI were performed preoperatively and repeated at 5 years follow up (3.5 to 6). MRI was comparative to the contra lateral shoulder and analyzed gleno-humeral dysplasia with the glenoid version and the coverage of the humeral head.

Results

Passive external rotation was improved by 63.3 (-12.5° preoperatively, range -20 to 0° and +50.8° at follow up, range 45 to 50°) without any limitation of internal rotation. Active antepulsion/abduction was improved by 90° on average (56.6° preoperatively and 156.7° at follow up). Remodeling of the glenoid was observed in all cases with glenoid version improved by 13° (-25.8° preoperatively, range -34 to -22 and -12.8° at follow up, range -21 to -4). The coverage of the humeral head was improved in all cases by 14.8% (25.6% preoperatively, range 0 to 50 and 40.4% at follow up, range 35 to 50). No complication was noted.

Conclusion and Significance

Shoulder arthroscopic release sparing the subscapularis is an efficient and reliable procedure in internal rotation contracture secondary to brachial plexus birth palsy. The MRI survey proved the positive effects on the remodeling of the shoulder.

Decision making in Sequela of Obstetrical palsy C5 C6

Philippe VALENTI -Paris

Retraction of the shoulder in internal rotation occurs frequently, sometimes early after the delivery in Obstetrical palsy C5 C6 +-C7. The diagnosis of this upper Erb's palsy should be done as soon as possible to avoid early bone and joint deformity of the gleno humeral joint. The baby is followed every two months to check the recovery of the contraction of the biceps(3 to 6 months), and to despite a lack of passive external rotation the arm at the chest and with 90° of abduction. Of course we test also the contraction of the deltoid and the triceps. If we have any doubt regarding a posterior dislocation of the shoulder, we perform standard X ray and CTScan to analyse the shape of the glenoid and the potential posterior subluxation or dislocation of the humeral head . An electromyography study is useful to confirm fibrillation in the muscles innervated by C5 C6 +-C7.

Therapeutic strategy should be done immediately after the diagnosis of the upper Erb's palsy :

A physiotherapy has to start as soon as possible with a good educational program of the parents.

Firstly If the contraction of the biceps with a flexion of the elbow is not recovered between 3 to 6 months (Tassing, Gilbert), a microsurgical exploration of the brachial plexus is done. Mostly, a microsurgical nerve graft of the superior trunk or one or two roots is possible; rarely, we do a neurotisation of the Musculo cutaneous nerve with the ulnar nerve(Oberlin procedure) for the flexion of the elbow and the XI to SS nerve for external rotation.

Before one year, we treat medial contracture with intensive physiotherapy and Botox injection into the subscapularis . This injection can be repeated.

If after conservative treatment, there is a limited passive external rotation we propose an arthroscopic arthrolysis of the GH joint : we do a resection of the rotator interval, the CH ligament and anterior capsule with sparing of the subscapularis tendon .

Between one and two year old, we combine this arthrolysis with a neurotisation of the suprascapular nerve by the spinal accessory nerve to restore active external rotation. This neurotisation can be done later if the infraspinatus has always some fibrillations. After two year, if the deltoid has not recovered, we can do a neurotisation of the axillary nerve with the postero lateral branch of the triceps.

When the child is older (>2-3 yo), we combine by arthroscopy an anterior arthrolysis of the gleno humeral joint with a tendon transfer of the latissimus dorsi on the cuff. If there is a posterior dislocation with a glenoid B2, this operation is not enough (with a high risk of redislocation) and we do a posterior osteotomy of the glenoid to maintain the reduction of the humeral head.